

# POCUS Journal

*Journal of Point-of-Care Ultrasound*

EMERGENCY MEDICINE. INTERNAL MEDICINE. CRITICAL CARE. CARDIOLOGY. PRIMARY CARE. ANESTHESIOLOGY. PULMONOLOGY

Research

Education

Practice

## Letter:

Point-of-Care Ultrasound Training and Credentialing for mid-late Career Emergency Physicians: Is it worth it?

## Case File:

Ultrasound Imaging of Quadriceps Tendon in a Recreational Golfer

## Case Report:

Elastofibroma Dorsi: Case Report with Point of Care Ultrasound Primary Care Applications

Adjunctive Use of Point of Care Ultrasound to Diagnose Compartment Syndrome of the Thigh

POCUS evaluation in acute kidney injury

Real-time Point-of-care Ultrasound for the Diagnosis and Treatment of Testicular Torsion

Diagnosis of Central Retinal Artery Occlusion in the Emergency Department Using POCUS: A Case Series

How Point-of-Care Ultrasound led to a diagnosis of May-Thurner Syndrome

## Research:

Taking the Pulse of POCUS: The State of Point-of-Care Ultrasound at a Pediatric Tertiary Care Hospital

Tricuspid Regurgitant Jet Velocity Point-of-Care Ultrasound Curriculum Development and Validation

Comparison of Clerkship Directors' expectations of physical examination skills with point-of-care ultrasound skills using the RIME framework

The Use of Thoracic Ultrasound to Predict Transudative and Exudative Pleural Effusion

Development and Evaluation of Resident-Championed Point-of-Care Ultrasound Curriculum for Internal Medicine Residents

Lung ultrasound to monitor disease severity and aid prognostication in COVID-19 pneumonia: a retrospective analysis of serial lung ultrasound assessments

## Review:

Development of a Cardiac Point-of-Care Ultrasound Curriculum for Anesthesia Residents in Brazil: It is Time to Act.

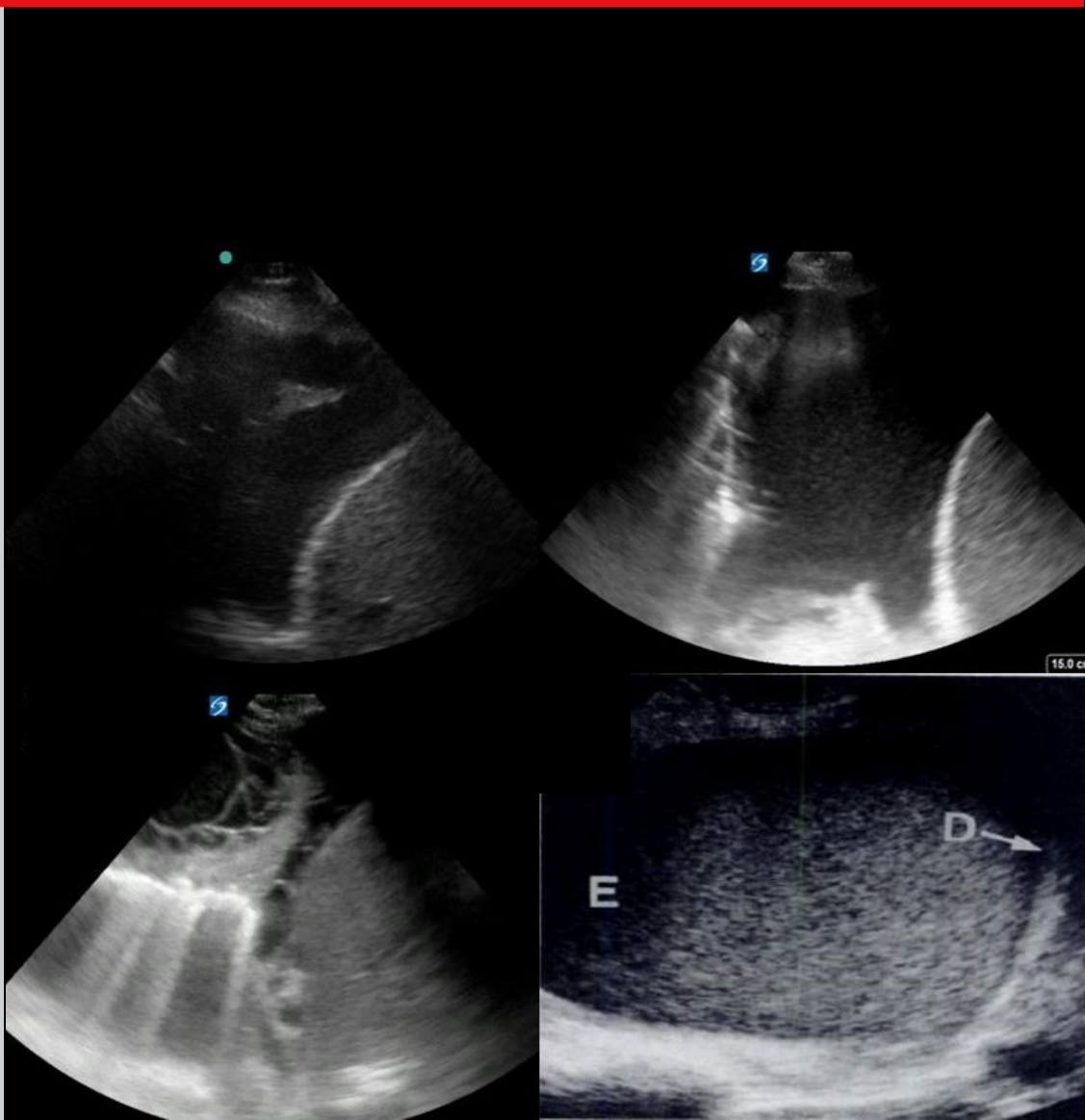


Table of Contents | Volume 6 | Issue 2 | November 2021

---

**Letter****56-57 Point-of-Care Ultrasound Training and Credentialing for mid-late Career Emergency Physicians: Is it worth it?**

Courtney M. Smalley, MD FACEP; Erin L. Simon, DO; McKinsey R. Muir, MHSA; Fernando Delgado, MSIE; Baruch S. Fertel, MD, MPA

**Case File****58-59 Ultrasound Imaging of Quadriceps Tendon in a Recreational Golfer**

Shawn D. Felton, EdD, LAT, ATC; Arie J. van Duijn, PT, MScPT, EdD

**Case Report****60-63 Elastofibroma Dorsi: Case Report with Point of Care Ultrasound Primary Care Applications**

Trent Mazer, MD; Karam Nabeel Gagi; Michael Bishop, MD

**64-66 Adjunctive Use of Point of Care Ultrasound to Diagnose Compartment Syndrome of the Thigh**

Neil Long, BMBS; Justin S. Ahn, MD; Daniel J. Kim, MD

**67-69 POCUS Evaluation in Acute Kidney Injury**

Vanessa A. Hoytfox, MD; Brittney C. Ward, DO; Emily J. Cox, PhD; Kang X. Zhang, MD FACP

**70-72 Real-time Point-of-care Ultrasound for the Diagnosis and Treatment of Testicular Torsion**

Rahul V. Nene, MD, PhD; Rachna Subramony, MD; Michael Macias, MD; Colleen Campbell, MD; Amir Aminlari, MD

**73-75 Diagnosis of Central Retinal Artery Occlusion in the Emergency Department Using POCUS: A Case Series**

Nicholas Cozzi, MD, MBA; Kendall Stevens, BS; Yeoshina Pillay, MD; David Moore MD; Matthew Flannigan, DO; Mariah Barnes, MD; Matthew Singh, MD; Melisa Gagraca, MD; Christian Kolacki, MD; Jennifer Bach, DO; Dale McNinch, MD; Drue Orwig, DO; Jeffrey Jones, MD

**76-79 How Point-of-Care Ultrasound Led to a Diagnosis of May-Thurner Syndrome**

Daniel L. Belkin, BFA; Mitchell D. Belkin, BA; Maedeh Ashrafi, MD; Charan Vegivinti, MD; Yung-Hsien Wang, MD; Leonidas Palaiodimos, MD

**Research****80-87 Taking the Pulse of POCUS: The State of Point-of-Care Ultrasound at a Pediatric Tertiary Care Hospital**

Peter Gutierrez, MD; Tal Berkowitz, MD; Lekha Shah, MD; Stephanie G. Cohen, MD

**88-92 Tricuspid Regurgitant Jet Velocity Point-of-Care Ultrasound Curriculum Development and Validation**

Zachary W. Binder, MD; Sharon E. O'Brien, MD; Tehnaz P. Boyle, MD, PhD; Howard J. Cabral, PhD; Joseph R. Pare, MD, MHS

**93-96 Comparison of Clerkship Directors' Expectations of Physical Examination Skills with Point-of-care Ultrasound Skills Using the RIME Framework**

Valérie Desjardins, BSc; Paul Pageau, MD; Barbara Power, MD; Isabelle Burnier, MD, MEd; Carolina Souza, MD, PhD; Warren J. Cheung, MD, MMed; Michael Y. Woo, MD

---

## Table of Contents (con't)

---

### **97-102 The Use of Thoracic Ultrasound to Predict Transudative and Exudative Pleural Effusion**

Peter T. Evans MD; Robert S. Zhang MD; Yulei Cao MS; Sean Breslin MD; Nova Panebianco MD, MPH; Cameron M. Baston MD, MSCE; David M. DiBardino, MD

### **103-108 Development and Evaluation of Resident-Championed Point-of-Care Ultrasound Curriculum for Internal Medicine Residents**

Leila Haghighat, MD; Hayley Israel, MD; Eric Jordan, MD; Ethan L. Bernstein, MD; Marilyn Varghese, MD; Benjamin M. Cherry, MD; Reinier Van Tonder, MD; Shyoko Honiden, MD; Rachel Liu, MD; Christopher Sankey, MD

### **109-116 Lung Ultrasound to Monitor Disease Severity and Aid Prognostication in COVID-19 Pneumonia: A Retrospective Analysis of Serial Lung Ultrasound Assessments**

Matthew Llewelyn Gibbins, MBChB DTMH FRCA FFICM; Quentin Otto, MA MB BChir DiMM; Paul Adrian Clarke, BM BSc MRCP FRCA FFICM; Stefan Gurney, MB BS MD (Res) FRCA FFICM

## Review

### **117-120 Development of a Cardiac Point-of-Care Ultrasound Curriculum for Anesthesia Residents in Brazil: It is Time to Act.**

Fabio de Vasconcelos Papa, TSA/FASE, MSsCH; Luiz Guilherme Villares da Costa, MD, PhD

---

# Point-of-Care Ultrasound Training and Credentialing for mid-late Career Emergency Physicians: Is it worth it?

Courtney M. Smalley, MD, FACEP<sup>1</sup>; Erin L. Simon, DO<sup>2</sup>; McKinsey R. Muir, MHSA<sup>1</sup>; Fernando Delgado, MSIE<sup>1</sup>; Baruch S. Fertel, MD, MPA<sup>1</sup>

(1) Cleveland Clinic Health System  
(2) Akron General Medical Center

Dear Editor:

Point-of-care ultrasound (POCUS) is becoming more prevalent in community emergency medicine (EM) practice with the current American College of Emergency Physician guidelines recommending POCUS training for all graduates from United States based residency programs as well as support for POCUS privileging by the American Medical Association [1-3]. However, in a recent survey of nonacademic EDs, it was found that most providers lack US training, credentialing, and quality assurance (QA) assessments of their POCUS studies [4]. In 2017, our healthcare system embarked on a system-wide credentialing process for POCUS to credential community physicians with little to no POCUS training [5]. After successful implementation and completion of the program in 2018, we sought to examine the group of mid to late career emergency physicians to assess how these physicians utilized POCUS longitudinally in their practice after credentialing and to assess QA issues with image acquisition and image interpretation in this cohort.

We performed a retrospective qualitative review of POCUS studies performed after a POCUS credentialing initiative for EM physicians was completed across 11 non-academic hospitals from January 1, 2017 to July 1, 2018, [5]. Credentialing in “Basic” POCUS required a completion of a dedicated POCUS course as well as a practice-based competency pathway which included Focused Assessment of Sonography in Trauma (FAST), aorta, and central line ultrasound training (Table 1). A practice-based pathway is defined as a pathway for practicing EM physicians who completed residency without POCUS training who undergo a series of introductory training, small group hands-on instruction, and practice with image acquisition and image interpretation of POCUS exams [1]. To complete the program within our healthcare system, EM physicians must complete the minimum number of exams (60 scans total in 3 modalities) to gain privileges in “Basic” POCUS. While they could complete other scan types during their credentialing period, they were not eligible to become credentialed in other scan types until the “Basic” POCUS

Table 1. Basic Point-of-Care Ultrasound Privileges

Credentialing Tier	Applications	Number of Scans Required
Basic Ultrasound  (all scan types required for completion)	General applications: focused assessment with sonography in trauma (FAST), US guided venous access placement, abdominal aorta aneurysm (AAA)	FAST: 25 scans AAA: 25 scans Central Line: 10 scans
Requirements for Point-of-Care Ultrasound Study		
1.Adequate image acquisition		
2.Adequate image interpretation		
3.Appropriate labeling of each image		

practice-based pathway was complete. For the physicians who successfully completed the practice-based pathway for competency by June 30, 2018, we reviewed the number of studies performed, the types of POCUS studies performed, and quality issues (image acquisition, image interpretation, and labeling of images) for 28 months after POCUS training. Each physician was designated by years from residency graduation as early-career (1-10 years), mid-career (11-20 years), or late (21 years or greater).

At the start of the program in January 2017, 26% (28/108) of community EM physicians were without POCUS privileges. 46% (13/28) physicians completed the program and became credentialed in “Basic” POCUS exams. The mean number of years of this group since residency graduation was 19 years, IQR 19.25 (13,25.5). 1 physician was excluded from the cohort as he left the healthcare system prior to July 1, 2018, when formal privileges took effect. From July 1, 2018 – Nov 1, 2020, a

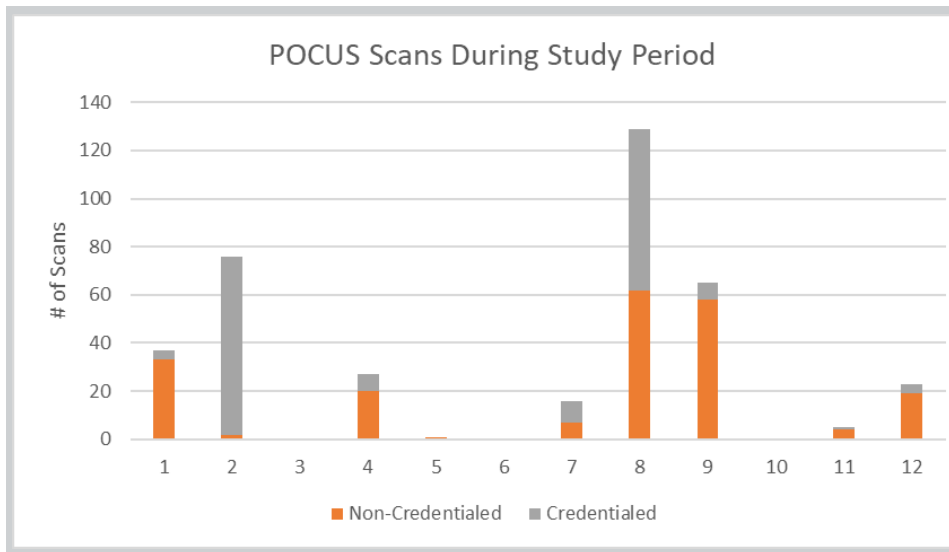


Figure 1. Credentialed and Non-Credentialed Physician Scans Performed after Completion of Basic POCUS Credentialing Program. Study Period: July 1, 2018 – November 1, 2020. Credentialed Scans defined as POCUS studies for which the physician has privileges and for which the study was a billable study. Non-Credentialed Scans defined as scans in other POCUS modalities for which the physician did not have privileges and the exam was a non-billable study.

total of 379 scans were performed by the 12 physicians. The mean number of scans performed per physician was 31. Three physicians performed zero scans. A total of 45% (172/379) of exams performed were eligible for documentation and billing for Basic POCUS privileges: FAST (N=158), aorta (N=13), central line (N=1), (Figure 1). Quality issues of inadequate image acquisition were identified on 17.7% (28/158) of FAST exams and 15.4% (2/13) of Aorta exams. There were no incidences of inappropriate image interpretation. 78% of studies were labeled appropriately.

A practice-based pathway to achieve POCUS credentialing for physicians without any training or experience in POCUS yielded very few credentialed billable POCUS studies. The physicians in this cohort had a median of 19 years since residency graduation with only physician in the cohort considered early-career. Overall, there were no incidences of inappropriate image interpretation but not all exams had appropriate image acquisition and labeling.

Our results raise the question of whether training of mid to late career emergency physicians in these “basic” POCUS studies is useful. We embarked on this retrospective review to examine this question as the amount of resources and time needed to train this cohort of physicians was significant. All of these physicians had no experience in POCUS. While we were able to put them through a standardized course to teach the introductory concepts of POCUS and become privileged in 3 POCUS exams, we found that very few physicians actually utilized POCUS longitudinally after achieving competency and privileges in these studies. Financial and resource implications include the time of the dedicated POCUS trainer, review of all studies while the physicians were completing a practice-based pathway for credentialing, and oversight as they practiced clinically in

their community sites with a quality assurance program.

Those points being considered, if only one patient had a shorter length of stay or was transferred to definitive care for trauma or aortic catastrophe based on POCUS training, then the training of mid to late career EM physicians in Basic POCUS may be worth the time and resource investment. Further investigations into the use of POCUS amongst late adopters of mid to late career EM physicians should be examined to determine how programs such as this affect resource utilization within a department, outcomes of patient care, and financial implications.

## Disclosures

None.

## References

1. Ultrasound Guidelines: Emergency, Point-of-Care and Clinical Ultrasound Guidelines in Medicine. *Annals of Emergency medicine*. 2017; 69(5):e27-e54.
2. American College of Emergency Physicians. ACEP Emergency ultrasound guidelines-2001. *Annals of Emergency medicine*. 2001; 38(4):470-81.
3. American Medical Association. Ultrasound Imaging: Hospitals. Privileging Ultrasound Imaging H-230.960 Accessed Jun 18, 2021. <https://policysearch.ama-assn.org/policyfinder/detail/Ultrasound%20Imaging?uri=%2FAMADoc%2FHOD.xml-0-1591.xml>
4. Amini R, Wyman MT, Hernandez NC, Guisto JA, Adhikari S. Use of Emergency Ultrasound in Arizona Community Emergency Departments *J Ultrasound Med*. 2017; 36(5):913-921.
5. Smalley CM, Fertel BS, Broderick E. Standardizing Point-of-Care Ultrasound Credentialing Across a Large Health Care System The Joint Commission Journal on Quality and Patient Safety. 2020; 46(8):471-476.



# Ultrasound Imaging of Quadriceps Tendon in a Recreational Golfer

Shawn D. Felton, EdD, LAT, ATC; Arie J. van Duijn, PT, MScPT, EdD

Florida Gulf Coast University, Fort Myers, FL 33965-6565, USA

## Abstract

The patient was a 69-year-old recreational golfer who injured his right . While walking between the 9th and 18th holes, he slipped on pine straw. Ultrasound images of the quadriceps tendon post-injury revealed a full-thickness tear of the Quadriceps tendon, Rectus Femoris and Vastus intermedius. The diagnosis was confirmed through MRI arthrogram imaging. The hypoechoic finding in the ultrasound exam demonstrated the imaging to be as precise in diagnosing a full thickness tear as the MRI. The patient underwent surgical repair of the Quadriceps Tendon and is currently progressing in rehabilitation.

## Case File

The patient was a 69-year-old recreational golfer who injured his right knee by slipping on pine straw, forcefully flexing his right knee under full weight-bearing. He indicated immediate sharp anterior knee pain and the inability to move his right leg. Upon examination, he presented with a palpable deformity proximal to the apex of the patella and moderate swelling at the lateral knee. The patient was unable to produce a quadriceps contraction and Passive Range of Motion (PROM) was limited due to pain. At time of injury, the patient had been prescribed three rounds of steroidal anti-inflammatory drugs for sinus infections, and had a prior history of a 3<sup>rd</sup> degree quadriceps tear of his contralateral knee 12 years prior. Based upon these clinical findings, ultrasound imaging was performed at point-of-care showing full thickness mid-tendon tear of the rectus femoris (see Figures 1 & 2). The patient was referred to an orthopedic surgeon, who performed MRI imaging (see Figure 3), confirming an avulsion of the superficial aspect of the rectus femoris from its patellar attachment and retracted proximally 1.9 cm and a complete tear. Subsequently, the patient underwent immediate open repair of the quadriceps tendon and began rehabilitation after 6 weeks.

This case illustrates the effectiveness of point of care ultrasound imaging identifying rectus femoris tendon tear. Prior research has indicated a high degree of clinical accuracy of ultrasound imaging for identifying partial and full thickness quadriceps tendon tears, comparable to MRI [1,2]. It is imperative for the clinician to ensure both short and long axis images to properly evaluate the extent of tissue damage.

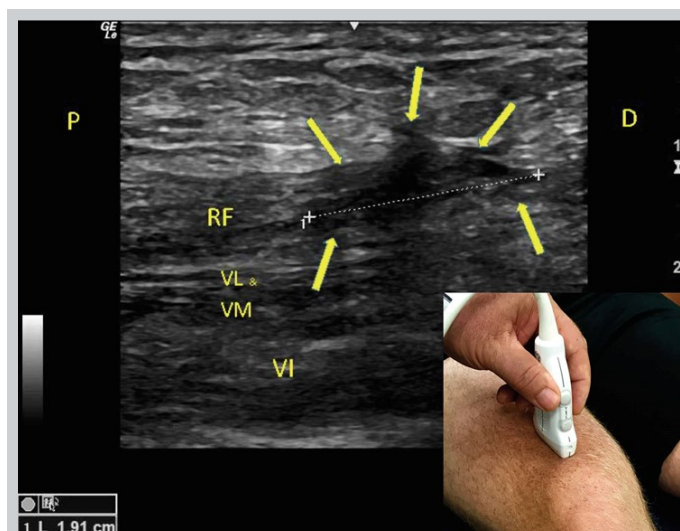


Figure 1. Post-injury long-axis ultrasound image of the Rectus Femoris (RF) (5-12 MHz linear transducer). The proximal and distal aspect of the rectus femoris exhibits a normal hyperechoic appearance, but a substantial hypoechoic area is noted (arrowheads), 1.9 cm which is suggestive of fluid and a full thickness mid-tendon tear of the rectus femoris. Also, mild hypoechoic signaling indicating fluid in the medial and lateral muscles indicating a strain with mild hypoechoic signaling deep indicating strain of vastus intermedius. Positioning of the ultrasound probe is seen in the bottom right-hand corner of the image. Abbreviations: P: proximal; D: distal; RF: rectus femoris; VL: vastus lateralis; VM: vastus medialis; VI vastus intermedius.

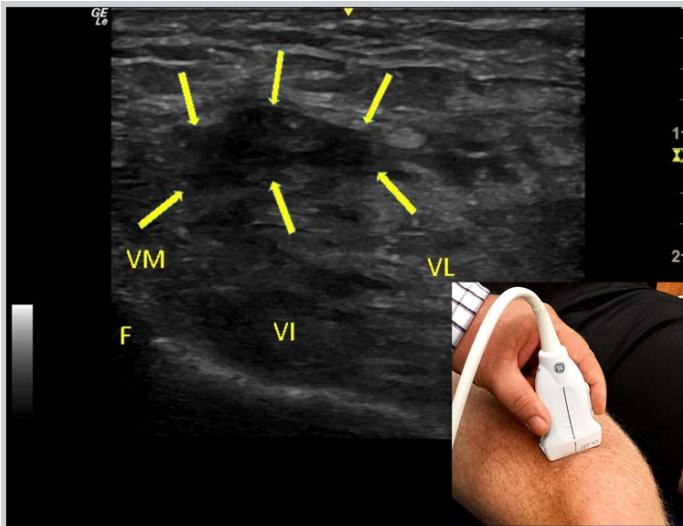


Figure 2. Post-injury short-axis ultrasound image of the Rectus Femoris. Disruption of the musculotendinous fibers of the rectus femoris can be visualized. A large hypoechoic gap in the rectus femoris is present, denoting the presence of significant fluid (arrows). Deeper areas of hypoechoic signaling indicating straining of the vastus medialis and lateralis and intermedius. Positioning of the ultrasound probe is seen in the bottom right-hand corner of the image. Abbreviations: F: femur; VL: vastus lateralis; VM: vastus medialis; VI vastus intermedius.

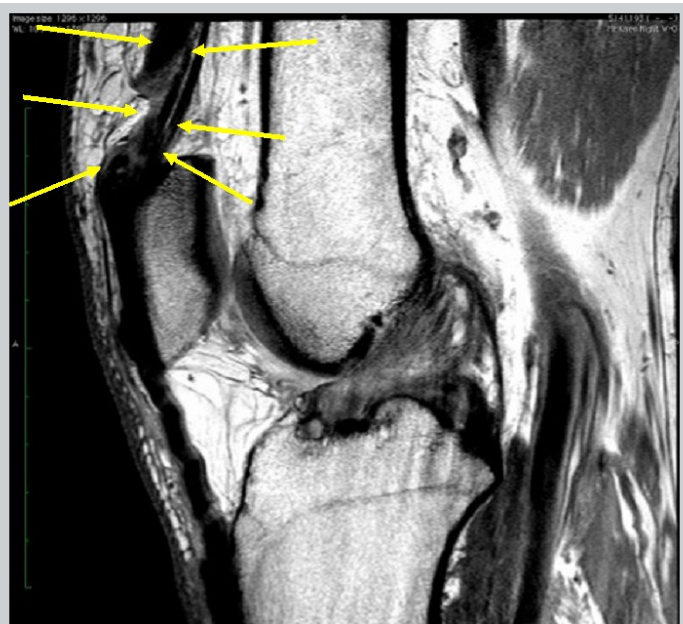


Figure 3. Post-injury MRI w/o contrast showing a portion of the quadriceps complex completely torn. The superficial aspect of the rectus femoris is avulsed from its patellar attachment and retracted proximally. Thinner smaller components of the vastus lateralis, vastus intermedius and vastus medialis remain intact. Arrowheads denote the torn quadriceps complex.

### Statement of Ethics

This study was approved by the Institutional Review Board of Florida Gulf Coast University

### Disclosures

The authors affirm they have no financial affiliation (including research funding) or involvement with any commercial organization that has a direct financial interest in any matter included in this manuscript, except as disclosed in an attachment and cited in the manuscript.

### References

1. Pasta G, Nanni G, Molini L, Bianchi S.. Sonography of the quadriceps muscle: Examination technique, normal anatomy, and traumatic lesions. *J Ultrasound*. 2010;13(2):76-84.
2. Foley R, Fessell D, Yablon C, et.al.. Sonography of traumatic quadriceps tendon tears with surgical correlation. *J Ultrasound Med*. 2015 34(5):805-10.

# Elastofibroma Dorsi: Case Report with Point of Care Ultrasound Primary Care Applications

Trent Mazer, MD; Karam Nabeel Gagi; Michael Bishop, MD

Mercy Health Department of Family Medicine, Grand Rapids, Michigan

## Abstract

Elastofibroma dorsi (ED) is an uncommon, benign, slow-growing soft tissue tumor with an unclear etiology. The growth often presents as a local deformity with mild pain or discomfort in the subscapular region of geriatric populations. The following paper discusses a 73 year old female with mildly painful ED who presented to her primary care physician. We further review current literature on epidemiology, utilization of point of care ultrasound (POCUS) and treatment options.

## Introduction

Elastofibroma dorsi (ED) are rare, benign soft tissue tumors located most frequently between the inferior aspect of the scapula and the thoracic chest wall. ED were first described by Jarvi and Saxen in 1961 [1]. Since then, there have been multiple case reports and case series on these tumors which have broadened our understanding of their potential etiologies [2-6]. The currently proposed mechanism for ED formation is a reactive process resulting from frictional irritation or trauma. Occasionally mucosal lesions have been reported, but are rare [7-11].

The typical presentation of ED includes a history of a unilateral mass on the inferior aspect of the scapula that causes swelling and discomfort, and in rare cases, pain [12]. On magnetic resonance imaging (MRI), the tumor is typically a solitary, poorly circumscribed, heterogeneous soft tissue mass [13].

## Case Presentation

A 73-year-old female presented to her primary care provider due to worsening shoulder pain. On initial presentation the patient described intermittent pain localized in the right mid medial scapular region that was so significant she could not use her vacuum. This pain started about 6 weeks prior to presentation with the development of a mass the size of "half an orange" in the area of her bra line, near the right shoulder blade. She denied any trauma to that area and could not recall the mass development timeline. Medical history did include a right shoulder reverse arthroplasty. A quick review of her records showed that a previous computed tomography of the chest performed a year prior to surgery was referenced and found to have no abnormalities in the area of question. The initial visit was over the telephone due to the patient's COVID-19 concerns, thus no physical exam was completed at that time.

A month later at a subsequent encounter the mass was examined and found to be approximately 5 cm x 5 cm in diameter. It was visible in the neutral position, localized just inferior to the right scapula, nontender to palpation and nonmobile (Figure 1). Laboratory findings were within normal limits. POCUS revealed a mass that was deep to the latissimus dorsi and resting above the inferior portion of the scapula. The mass was heterogeneous, nonencapsulated with similar echogenicity to

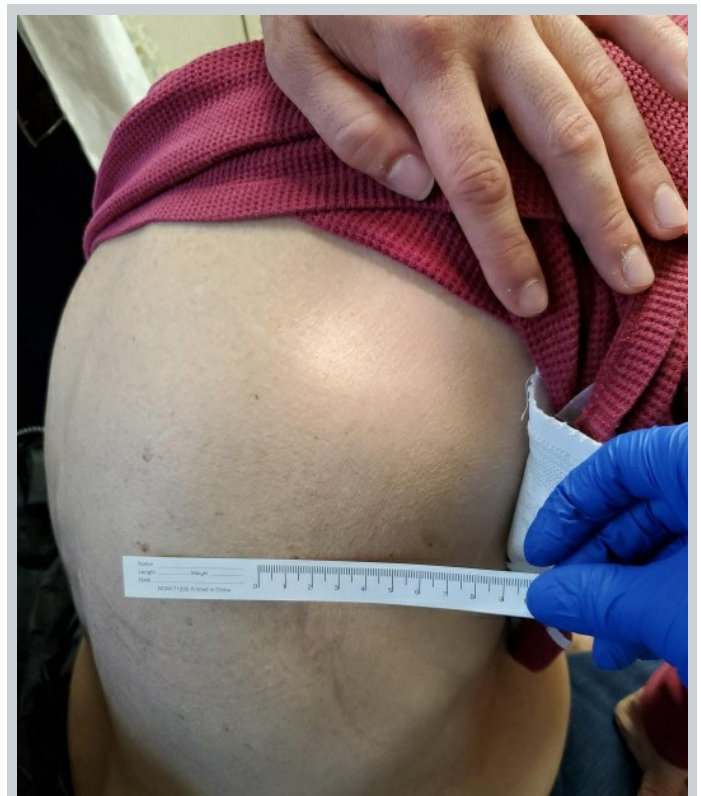


Figure 1. Picture of the Right posterior thorax. Visualization of the mass was possible from neutral positioning.



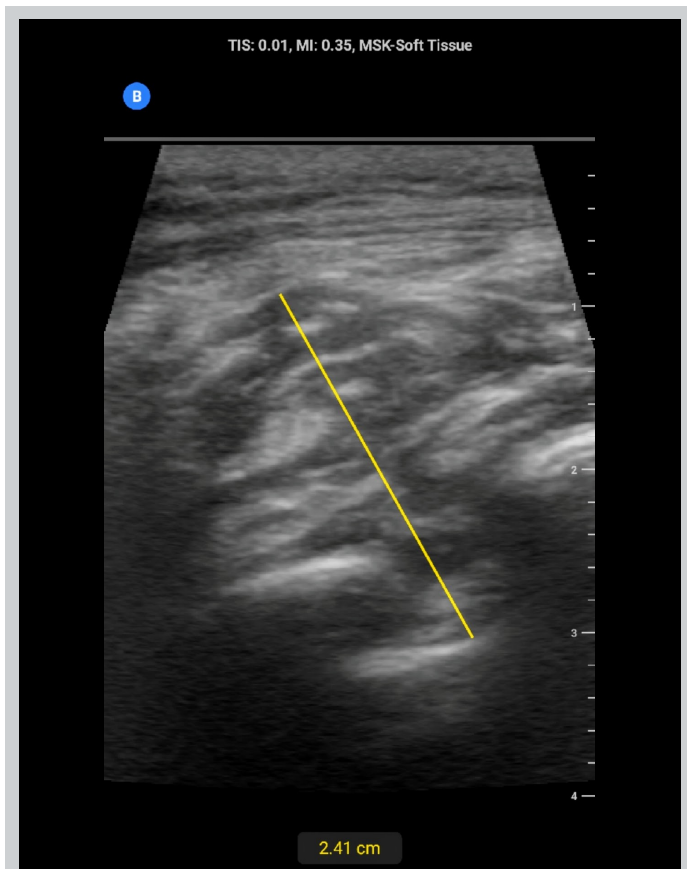


Figure 2. POCUS at initial office visit of the right posterior thorax below the scapula. Images include proximal long right lateral orientation just below the shoulder blade showcasing heterogeneous soft tissue mass located deep to the superficial musculature.

subcutaneous fat and interweaving hypoechoic regions indicating a possible inflammatory response with fluid buildup (Figure 2). Doppler was not utilized during this exam.

A formal ultrasound of the mass and chest Xray were ordered after the initial visit (Figure 3). The ultrasound completed a doppler examination that did not reveal any abnormal blood flow to the region. Results at this point were inconclusive and the primary care provider discussed the case with general surgery. An MRI was subsequently ordered and resulted in the diagnosis of ED (Figure 4.) The patient continued to have significant discomfort, thus surgical referral was placed for possible resection.

### Epidemiology

ED is a rare, benign, slow growing soft tissue tumor that typically presents in the subscapular and infrascapular region [1]. Some more rare locations of presentation include the orbit, mediastinum and greater omentum [14].

ED is most commonly found in the elderly, specifically over 55 years of age with a mean age of 60 years at

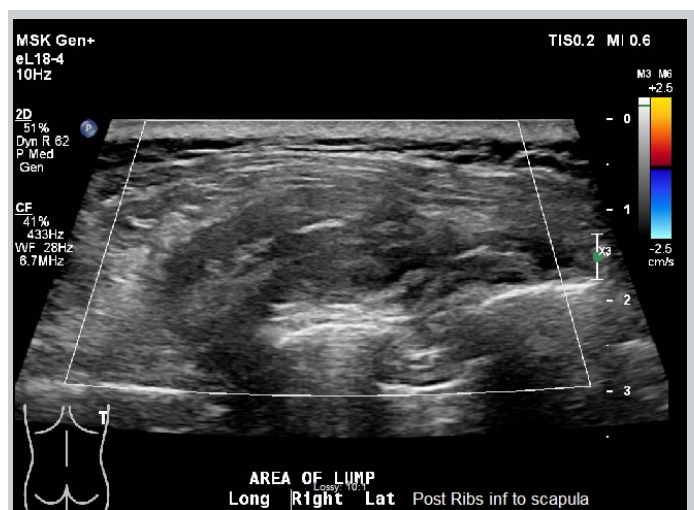


Figure 3. Formal Ultrasound. Posterior right chest along the inferior aspect of the scapula superficial to the scapula and along the chest wall, a 4.8 x 4.1 x 1.9 cm heterogeneous soft tissue mass without significant flow seen on color Doppler imaging. It is located deep to the superficial musculature. Initial impression of a complex nonspecific soft tissue mass reflecting swelling from surgery or an injury. Neoplasm was not excluded.

diagnosis [12]. Children have not been exempt with some literature finding cases in younger ages [14-18]. Prevalence in the elderly ranges from 2% to 24% in women and 11% for men as reported in an autopsy series [15].

The cause has not been determined, but ED is more common in people with large amounts of activity involving the shoulder [14,15]. This has led to the conclusion that increased friction between the scapula and the thoracic wall may be associated with the development of ED. Microtrauma is implicated to cause degeneration of collagen and reactive hyperproliferation of fibroblastic tissue in that region [15,16]. It is difficult to explain the development of ED in sites not involved in mechanical overload leading authors to consider ED as more of a normal aging process or genetic predisposition [14,17].

### Imaging Applications

Ultrasound examination as a screening test can quickly identify masses with concerning features such as a diameter larger than 5 cm, location below the muscle, heterogeneity and increased doppler flow [13]. Figure 5 can be referenced as an example of a benign soft tissue mass for comparison. The decision to move towards definitive diagnosis with an MRI could be expedited in concerning cases if POCUS was used in the primary care setting. Avoiding the distress and service demands of unnecessary urgent cancer referrals [13,14]. In addition




Figure 4. MRI of the Scapula. Mass deep to the right latissimus dorsi and serratus anterior muscles at and extending inferior to the distal tip of the scapula. This measures 6.9 x 1.5 cm, composed of soft tissue components of similar signal intensity in the skeletal muscle with small foci of intermixed fat and mild heterogeneous postcontrast enhancement. Impression of the exam was consistent with elastofibroma dorsi. [A:Anterior, S: Superior].

primary care POCUS has been found to be a reliable tool in lipoma evaluations with proper training [18]. On re-evaluation of the initial POCUS images in this case, the heterogenous, disorganized structure underneath the superficial muscle that was increasing in size and pain could have led directly to MRI evaluation. The official ultrasound and radiography offered no further diagnostic clues beyond a negative doppler, and in this case could have been bypassed for surgical evaluation or MRI since the diagnosis was uncertain [12,13,19].

### Treatment

Upon definitive diagnosis of ED, treatment depends on severity of symptoms. Asymptomatic patients with ED do not benefit from excision as ED is a benign process. Clinical follow up proves to be adequate for this population [5,20]. When ED causes significant symptoms for the patient or the diagnosis is not definitive, curative marginal resection is recommended [5,19]. No cases of malignant transformation have been recorded and beyond incomplete excision, recurrence is rare [16,19,21,22].

In conclusion, understanding the presentation of ED

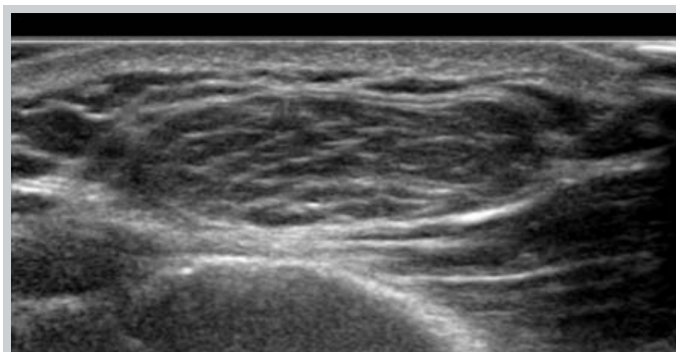


Figure 5. Example of benign lipoma with sonographic appearance of well organized, heterogeneous echogenicity with multiple clearly defined long smooth continuous internal echogenic lines parallel to the long axis of the lesion superficial to any musculature [23].

could help patients avoid unnecessary procedures. The elderly and asymptomatic patients are most at risk, and simple follow up is most often sufficient. Only those who are symptomatic should be provided the opportunity to proceed with surgical management.

### Declaration of patient consent

The authors certify that they have obtained all appropriate patient consent forms. In the form the patient has given her consent for her images and other clinical information to be reported in the journal. The patient understands that her name and initials will not be published and due efforts will be made to conceal her identity, but anonymity cannot be guaranteed.

### Disclosures

None.

### References

1. Jarvi O, Saxen E. Elastofibroma dorsi. *Acta Pathol Microbiol Scand Suppl.* 1961;51(Suppl 144):83-4.
2. Ochsner JE, Sewall SA, Brooks GN, et al. Best cases from the AFIP: Elastofibroma dorsi. *Radiographics.* 2006;26(6):1873-6.
3. Falidas E, Arvanitis D, Anyfantakis G, et al. Painful Elastofibroma dorsi: A report of a case and a brief review of the literature. *Case Rep Orthop.* 2013;2013:794247.
4. Hocar H, Buffard V, Ortonne N, et al. Bilateral elastofibroma dorsi. *Ann Dermatol Venerol.* 2012;139(1):41-5.
5. Darling MR, Kutalowski M, MacPherson DG, et al. Oral Elastofibromatous Lesions: A review and case series. *Head Neck Pathol.* 2011;5(3):254-8.
6. Cavallasca JA, Sohn DI, Borgia AR, et al. Elastofibroma dorsi: review of 4 cases. *Reumatol Clin.* 2012;8(6):358-60.
7. Potter TJ, Summerlin DJ, Rodgers SF. Elastofibroma: the initial report in the oral mucosa. *Oral Surg Oral Med Oral Pathol Oral Radiol Endod.* 2004;97(1):64-7.
8. Manchandu R, Foote J, Alawi F. Elastofibroma presenting as an oral soft tissue mass. *J Oral Pathol Med.* 2008;37(2):125-6.
9. Märkl B, Kerwel TG, Langer E, et al. Elastosis of the colon and the

ileum as polyp causing lesions: a study of six cases and review of the literature. *Pathol Res Pract*. 2008;204:395-9.

10. Tosios KI, Economou I, Vasilopoulos NN, et al. Elastofibromatous changes and hyperelastosis of the oral mucosa. *Head Neck Pathol*. 2010;4(1):31-6.

11. Nonaka CF, Rego DM, Miguel MC, et al. Elastofibromatous change of the oral mucosa: case report and literature review. *J Cutan Pathol*. 2010;37:1067-71.

12. Go PH, Meadows MC, DeLeon EM, et al. Elastofibroma dorsi: a soft tissue masquerade. *Int J Shoulder Surg*. 2010;4(4):97-101.

13. Lakkaraju A, Sinha R, Garikipati R, et al. Ultrasound for initial evaluation and triage of clinically suspicious soft-tissue masses. *Clin. Radiol*. 2009;64:615-21.

14. Rowbotham E, Bhuva S, Gupta H, et al. Assessment of referrals into the soft tissue sarcoma service: Evaluation of imaging early in the pathway process. *Sarcoma*. 2012;2012:1-5.

15. Naylor MF, Nascimento AG, Sherrick AD, et al. Elastofibroma dorsi: Radiologic findings in 12 patients. *AJR Am J Roentgenol*. 1996;167:683-7.

16. Nagamine N, Nohara Y, Ito E. Elastofibroma in Okinawa. A clinicopathologic study of 170 cases. *Cancer*. 1982;50(9):1794-805.

17. Jarvi OH, Lansimies PH. Subclinical elastofibromas in the scapular region in an autopsy series. *Acta Pathol Microbiol Scand A*. 1975;83(1):87-108.

18. Rahmani G, McCarthy P, Bergin D. The diagnostic accuracy of

ultrasonography for soft tissue lipomas: a systematic review. *Acta Radiol Open*. 2017;6(6):2058460117716704.

19. Daigeler A, Vogt PM, Busch K, et al. Elastofibroma dorsi—differential diagnosis in chest wall tumours. *World J Surg Oncol*. 2007;5:15.

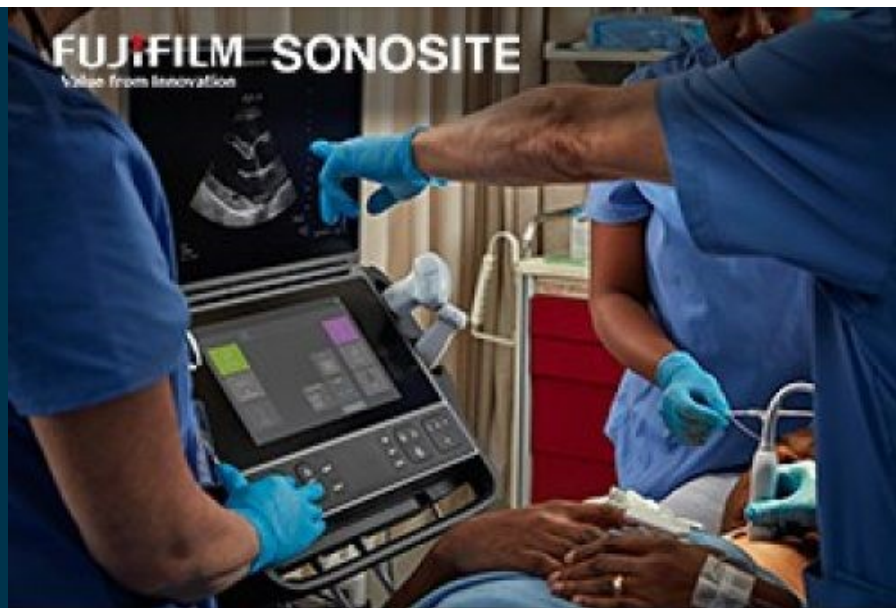20. Muratori F, Esposito M, Rosa F, et al. Elastofibroma dorsi: 8 case reports and a literature review. *J Orthop Traumatol*. 2008;9(1):33-7.

21. Giebel GD, Bierhoff E, Vogel J. Elastofibroma and pre-elastofibroma—a biopsy and autopsy study. *Eur J Surg Oncol*. 1996;22(1):93-6

22. Kransdorf MJ, Meis JM, Montgomery E. Elastofibroma: MR and CT appearance with radiologic-pathologic correlation. *AJR Am J Roentgenol*. 1992;159(3):575-9.

23. Vivitmongkonchai K, Wangcharoenrung D, Kintarak J, et al. Sonographic Appearance of Soft Tissue Lipomas. *J Med Assoc Thai*. 2016;99(4):69-74

Visit the online article: <https://doi.org/10.24908/pocus.v6i2.15184>



**Because every detail matters.**  
**Sonosite PX.**

[Learn more](#)



# Adjunctive Use of Point of Care Ultrasound to Diagnose Compartment Syndrome of the Thigh

Neil Long, BMBS<sup>1,2</sup>; Justin S. Ahn, MD<sup>2,3</sup>; Daniel J. Kim, MD<sup>2,4</sup>

- (1) Department of Emergency Medicine, Burnaby General Hospital, Burnaby, British Columbia  
 (2) Department of Emergency Medicine, University of British Columbia, Vancouver, British Columbia  
 (3) Department of Emergency Medicine, Royal Columbian Hospital, New Westminster, British Columbia  
 (4) Department of Emergency Medicine, Vancouver General Hospital, Vancouver, British Columbia

## Abstract

Compartment syndrome is a medical emergency and must be considered in patients who present with severe limb pain. Compartment syndrome is a clinical diagnosis, classically described as presenting with the 5 'P's (pain, pulselessness, pallor, paraesthesia, and paralysis). Apart from pain, the other findings signify acute arterial obstruction and would be late findings. We present a case of a 31-year-old male in which point of care ultrasound (POCUS) expedited this diagnosis by demonstrating a large thigh hematoma in the anterior compartment. This prompted emergent orthopedic surgery consultation, and the diagnosis of compartment syndrome was confirmed both at the bedside and in the operating room. Compartment syndrome can be a challenging diagnosis, especially early in the course of illness. While POCUS should not be used in isolation in the assessment of possible compartment syndrome, it can be used as an adjunct in the workup, especially if it identifies an underlying cause.

## Introduction

Compartment syndrome is an emergency condition that while uncommon should be part of any emergency physician's differential when presented with a patient in severe limb pain. If left untreated, irreversible muscle necrosis can occur resulting in loss of limb or life-threatening hyperkalemia resulting in ventricular dysrhythmias and potentially death. Compartment syndrome is a clinical diagnosis, classically characterized by the 5 'P's (pain, pulselessness, pallor, paresthesia,

and paralysis). However, in this case report we present a case where only a few of the classic findings were present, and the use of point of care ultrasound (POCUS) expedited diagnosis and management.

## Case Report

A 31-year-old male presented to the emergency department (ED) with acute thigh pain and swelling. He had been struck as a pedestrian by a car at low speed 10 days prior, with the main impact to his right thigh. He was assessed in the ED at that time, diagnosed with minor

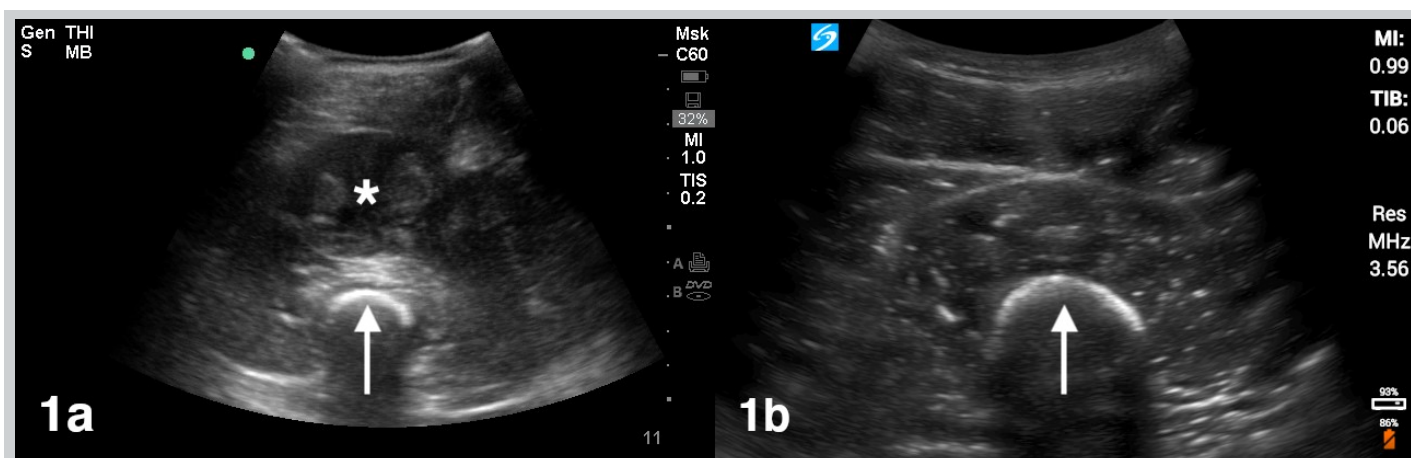


Figure 1. a) Ultrasound image of a large hematoma (asterisk) in the anterior thigh, appearing as a well circumscribed collection of mixed echogenicity. The femur (arrow) is the hyperechoic structure with posterior shadowing. b) Ultrasound image of a normal anterior thigh demonstrating normal sonographic muscle architecture with the femur (arrow) in the far field.



soft tissue contusions, and discharged home. He had been having minimal discomfort, but that morning, he developed sudden onset, severe right thigh pain and swelling, and an inability to bear weight. His past medical history included von Willebrand disease and Noonan syndrome complicated by pulmonary stenosis. He was on no medications. On physical examination, he was afebrile with normal vital signs but appeared to be in moderate discomfort secondary to pain. The right thigh was swollen and firm, particularly over the anterior compartment. There was no redness or warmth. Severe pain was elicited with passive knee flexion and extension, but more so with knee flexion. The extremity remained neurovascularly intact.

POCUS demonstrated a well circumscribed collection of mixed echogenicity in the anterior thigh consistent with a hematoma measuring 3.6 cm in the anteroposterior dimension, 8.2 cm in the transverse dimension, and 11.5 cm in the longitudinal dimension. The typical muscular anatomy of the thigh appeared distorted as a result (Figure 1a, online Video S1) compared to the normal contralateral thigh. (Figure 1b). On color Doppler, there was no increase in vascularity either within or surrounding the hematoma (Figure 2, online Video S2).

Orthopedic surgery was emergently consulted, and the orthopedic team performed compartment pressure measurements with a Stryker device. The pressure in the anterior compartment was >65 mm Hg. The patient was brought to the operating room and underwent urgent fasciotomy of the right anterior and posterior compartments. Once the fascia lata was opened, the vastus lateralis muscle bulged out through the fascial split, reflecting the abnormally high pressure in the anterior compartment. Although the musculature in the anterior compartment was bruised, it appeared healthy with normal color and contractility, speaking to the timeliness of the diagnosis and operative management. The patient required a delayed skin graft, and ultimately made a full recovery.

## Discussion

Compartment syndrome is a condition where intra-compartmental pressures increase to the point of causing a decrease in perfusion pressure, which can lead to ischemia, and if left untreated, irreversible muscle necrosis. Compartment syndrome is a clinical diagnosis. Pain out of proportion to clinical findings and pain elicited with passive extension are typical early findings, as in our patient. The classical 5 'P's of compartment syndrome (pain, pulselessness, pallor, paresthesia, and paralysis) are actually signs of acute arterial obstruction, and other than pain, would be late findings [1].

The delayed presentation of this case of compartment

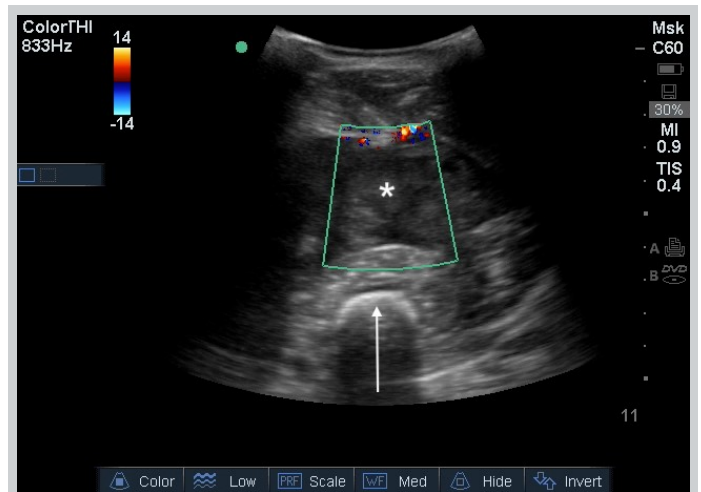


Figure 2. Ultrasound color Doppler image of a large hematoma (asterisk) in the anterior thigh, appearing as a well circumscribed collection of mixed echogenicity without vascularity. The femur (arrow) is the hyperechoic structure with posterior shadowing.

syndrome was atypical, as most cases occur within 24-48 hours of injury. However, bleeding disorders, such as von Willibrand disease, can contribute to delayed hematoma formation. Notably, the thigh is an unusual location for compartment syndrome. Suzuki et al reported only 8 patients with compartment syndrome of the thigh out of 3,658 blunt trauma patients seen at their institution over an 8-year period [2]. Compartment syndrome involving the thigh has been associated with trauma, post-surgery (especially orthopedic or vascular surgery), tumor infiltration, exercise, snake bite, drugs, anticoagulants, and coagulopathy [3].

Unfortunately, clinical assessment, especially based on classic signs and symptoms, has low sensitivity for the diagnosis of compartment syndrome. If the clinical assessment is equivocal, it is recommended that compartment pressures be measured. Either an absolute pressure >30 mm Hg or a delta pressure <30 mm Hg, defined as the difference between diastolic blood pressure and measured compartment pressure, should trigger emergent orthopedic consultation [1].

Use of POCUS may facilitate the diagnosis of compartment syndrome by identifying an underlying cause. In this case, immediate detection of a large hematoma within the anterior compartment along with severe pain prompted emergent orthopedic consultation. Other case reports describe the use of ultrasound in identifying the presence of a thigh hematoma to adjunctively assist in ultimately diagnosing compartment syndrome [3,4]. These findings can also provide the clinician with confidence to expedite orthopedic consultation, especially if the orthopedic specialist is

resistant or unwilling to see the patient in a timely manner. On ultrasound, hematomas typically have the appearance of rounded collections that appear hypoechoic in the acute phase and more hyperechoic with age. They should not have any Doppler flow. Ultrasound may identify alternative pathology like abscess, necrotizing fasciitis, muscle tears, myositis, or rhabdomyolysis [5]. However, it is important to note that ultrasound cannot rule out compartment syndrome.

## Conclusion

Compartment syndrome can be a challenging diagnosis, especially early on in the course of illness, as many less emergent conditions can also cause extremity pain. While POCUS should not be used in isolation in the assessment of possible compartment syndrome, it can be used as an adjunct in the workup, especially if it identifies a large hematoma or other underlying cause.

## Conflicts of Interest

NL and JSA do not report any conflicts of interest. DJK is on the medical advisory board of Clarius Mobile Health.

## References

1. von Keudell AG, Weaver MJ, Appleton PT, et al. Diagnosis and treatment of acute extremity compartment syndrome. *Lancet* 2015; 386:1299-1310.
2. Suzuki T, Moirmura N, Kawai K, Sugiyama M. Arterial injury associated with acute compartment syndrome of the thigh following blunt trauma. *Injury* 2005; 36:151-159.
3. Khan SK, Thati S, Gozzard C. Spontaneous thigh compartment syndrome. *West J Emerg Med* 2011; 12:134-138.
4. Eicken JJ, Morrow D. Limb threatening thigh hematoma diagnosis accelerated by emergency physician bedside ultrasound. *SAGE Open Med Case Rep* 2019; 7:2050313X19848589.
5. Connell MJ, Wu TS. Bedside musculoskeletal ultrasonography. *Crit Care Clin* 2014; 30:243–73.

## POCUS Evaluation in Acute Kidney Injury

Vanessa A. Hoytfox, MD<sup>1</sup>; Brittney C. Ward, DO<sup>1</sup>; Emily J. Cox PhD<sup>2</sup>; Kang X. Zhang MD FACP<sup>1</sup>

(1) Providence Health Care, Providence Internal Medicine Residency Spokane, Spokane, WA, United States of America

(2) Providence Health Care, Providence Medical Research Center, Spokane, WA, United States of America

### Abstract

Acute kidney injury is a common clinical problem encountered in general internal medicine. The evaluation of acute kidney injury is mainly driven by the patient's clinical history, physical exam, and laboratory investigation including urinalysis and urine sediment examination. Point of care ultrasound (POCUS) may be a useful tool to help clinicians to narrow and/or prioritize differential diagnosis in patients presenting with acute kidney injury. Here we present a case of a 67-year-old male presenting with dysuria, fevers, and flank pain along with elevation in serum creatinine who was admitted with concern for acute kidney injury secondary to complicated urinary tract infection. Subsequent kidney POCUS of the kidneys and bladder showed bilateral anechoic fluid collection within the kidney sinus with dilated calyces suggestive of bilateral hydronephrosis, most likely due to a new diagnosis of benign prostatic hyperplasia. This case demonstrates the use of POCUS-obtained valuable diagnostic information and subsequent therapeutic management for this patient presenting with suspected acute kidney injury.

### Description of the case

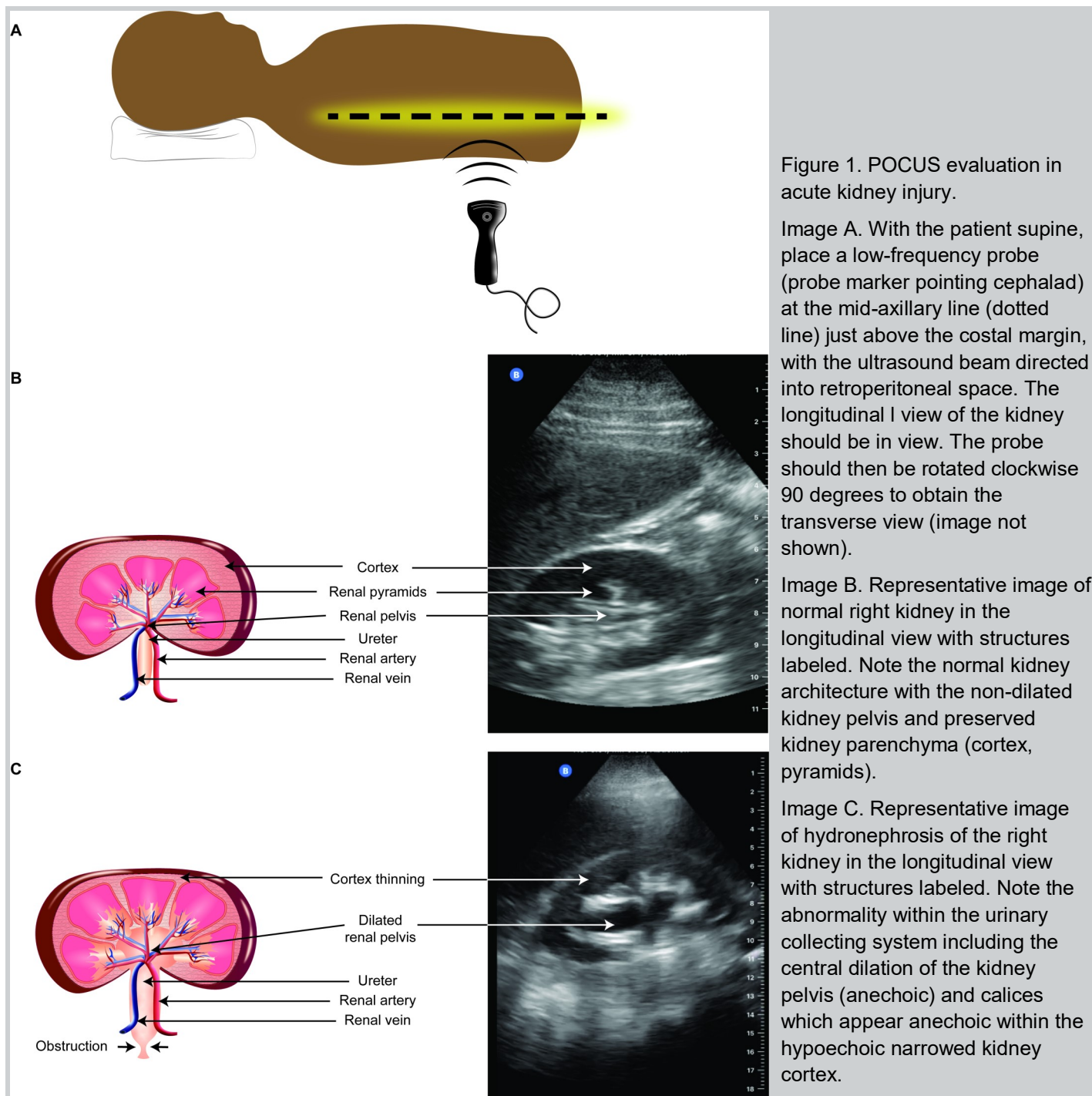
A previously healthy 67-year-old male presented to the emergency department after 4 days of bilateral flank pain consistent with kidney colic. The pain was associated with dysuria, fevers, urinary hesitancy, and frequency. He was afebrile and hemodynamically stable on initial presentation. Physical exam was significant for lower abdominal and left costovertebral angle tenderness. Relevant labs showed a leukocytosis of 22,000 cell/ $\mu$ L with 13% bands and creatinine of 2.61 mg/dL without a known prior baseline. Urinalysis was positive for pyuria, blood, and nitrite. The patient received broad-spectrum antibiotics and was admitted for presumed acute kidney injury secondary to pyelonephritis. The admitting resident team performed POCUS evaluation of the kidneys and found an anechoic collection bilaterally within the kidney sinus along with dilated calyces (Figure 1). Additional color flow Doppler was applied to the anechoic space and confirmed the absence of a vascular component. These findings supported the determination that kidney injury was likely multifactorial due to obstructive nephropathy in addition to pyelonephritis. A Foley catheter was placed immediately for bladder decompression. Comprehensive kidney and bladder ultrasonography was performed by radiology within 2 hours of POCUS exam. This confirmed severe bilateral hydronephrosis as well as mobile echogenic debris and thickened bladder wall suggestive of cystitis. Left kidney size was 12.8 cm and right kidney size was 14.3 cm. Post-void residual bladder volume was ~400 ml and enlarged prostate was visualized. Urology was consulted and the patient required bilateral ureteral stent placement. The most likely diagnosis was

pyelonephritis complicated by hydronephrosis secondary to enlarged benign prostatic hyperplasia. The patient's clinical symptoms markedly improved and creatinine improved to 2.46 mg/dL. He was discharged with oral antibiotics and outpatient urology follow-up.

This case demonstrates that POCUS of the kidneys and bladder can assist providers in visualizing complications of urinary obstruction and thus guide further diagnostic imaging and decision-making. Evaluation of acute kidney injury is a common clinical problem encountered in general internal medicine, and post-obstructive acute kidney injury is often considered as part of differential diagnosis. In this case, the detection of anechoic fluid collection in the kidney sinus by POCUS shifted the diagnostic momentum as it prompted timely management and evaluation of obstructive uropathy.

The American College of Radiology (ACR) Appropriateness Criteria for acute pyelonephritis does not recommend imaging in uncomplicated cases of pyelonephritis [1]. However, in complicated cases, ultrasonography offers a low-risk and rapid imaging acquisition modality [1]. In a multicenter, randomized trial comparing initial imaging methods (POCUS vs radiology ultrasound vs abdominal CT) in patients with suspected nephrolithiasis, initial ultrasonography led to significantly lower 6-month cumulative radiation exposure in both ultrasonography groups compared with the CT group, without significant differences in diagnostic accuracy, treatment outcomes, or re-admissions [2].

While it does not replace the need for comprehensive imaging, the use of POCUS in the evaluation of acute



kidney injury allows quick and accurate ascertainment of the need for further diagnostic/therapeutic interventions. Previous studies have shown that POCUS can quickly detect hydronephrosis with a sensitivity of 77-90% and specificity of 71-96% [3, 4, 5, 6]. Emergency physicians can correctly identify hydronephrosis via POCUS with an accuracy of 81% and a positive predictive value (PPV) of 91% compared to CT scans [5]. Ultrasound performed by emergency physicians has shown comparable results to CT in detection of severity of hydronephrosis, in which hydronephrosis detected by emergency physicians using POCUS had a PPV of 88% and likelihood ratio of +2.91

[7]. Skill acquisition is a minimal barrier: indeed, accuracy of POCUS is not significantly limited by training level or scanning experience [3, 8] and even untrained emergency physicians can learn to accurately detect or rule out hydronephrosis after a 2 day, 16-hour training course [8, 9]. POCUS is commonly performed by rural physicians with various levels of POCUS training in New Zealand in the evaluation of urinary retention to identify hydronephrosis with a sensitivity of 90% and specificity of 96% [6]. In a study evaluating the comparative diagnostic accuracy of hydronephrosis with POCUS versus CT scan, research showed that physicians with as little as 2



weeks of POCUS experience were able to detect hydronephrosis with 70% sensitivity and 73% specificity [10].

This case illustrates that POCUS can guide focused advanced imaging such as comprehensive ultrasound of kidneys and bladder performed by radiology or computed tomography of the abdomen and pelvis. Data to date indicate that POCUS is fast, accurate, and is an easy skill to acquire and train. Thus, integrating POCUS in the evaluation of acute kidney injury may decrease time to intervention, avoid needless radiation exposure, control associated costs, and perhaps reduce length of stay without variation in quality of diagnostic accuracy.

### Statement of ethics/consent approval

HIPAA authorization was obtained from the patient to permit publication of this case report. The Providence St. Joseph Health Institutional Review Board determined that this case report did not constitute research or require Institutional Review Board review.

### Disclosures

The authors have no disclosures to report.

### References

1. Nikolaidis P, Dogra V, Goldfarb S, et al. ACR Appropriateness criteria: Acute pyelonephritis. *Journal of American College of Radiology* 2018; 12(11S): S232-S239.
2. Smith-Bindman R, Aubin C, Bailitz J, et al. Ultrasonography versus computed tomography for suspected nephrolithiasis. *New England Journal of Medicine* 2014; 371: 1100-1110. DOI: 10.1056/NEJMoa1404446
3. Sibley S, Roth N, Scott C, et al. Point-of-care ultrasound for the detection of hydronephrosis in emergency department patients with suspected renal colic. *Ultrasound J* 2020; 12(1):31. <https://pubmed.ncbi.nlm.nih.gov/32507905/>.
4. Riddell J, Case A, Wopat R, Beckham S, et al. Sensitivity of emergency bedside ultrasound to detect hydronephrosis in patients with computed tomography-proven stones. *Western Journal of Emergency Medicine: Integrating Emergency Care with Population Health* 2014; 15 (1). <https://pubmed.ncbi.nlm.nih.gov/24578772/>.
5. Watkins S, Bowra J, Sharma P, et al. Validation of emergency physician ultrasound in diagnosing hydronephrosis in ureteric colic. *Emerg Med Australasia* 2007;19(3):188-95. <https://pubmed.ncbi.nlm.nih.gov/17564683/>.
6. Nixon G, Blattner K, Muirhead J & Kerse N. Rural point-of-care ultrasound of the kidney and bladder: quality and effect on patient management. *Journal of primary health care* 2018; 10(4), 324–330. <https://doi.org/10.1071/HC18034>. <https://pubmed.ncbi.nlm.nih.gov/31039961/>.
7. Leo M, Langlois B, Pare J, et al. Ultrasound vs. computed tomography for severity of hydronephrosis and its importance in renal colic. *West J Emerg Med* 2017; 18(4): 559-568.
8. Javaudin F, Mounier F, Pes P, et al. Evaluation of a short formation on the performance of point-of-care renal ultrasound performed by physicians without previous ultrasound skills: prospective observational

study. *Crit Ultrasound J* 2017; 9(1):23. <https://pubmed.ncbi.nlm.nih.gov/29124412/>.

9. Schoenfeld E, Pekow P, Shieh M, et al. The diagnosis and management of patients with renal colic across a sample of US Hospitals: high CT utilization despite low rates of admission and inpatient urologic intervention. *PLoS ONE* 2017; 12(1):e0169160. <https://pubmed.ncbi.nlm.nih.gov/28046001/>.

10. Herbst M, Rosenberg G, Daniels B, et al. Effect of provider experience on clinician-performed ultrasonography for hydronephrosis in patients with suspected renal colic. *Annals of Emergency Medicine* 2014; 64(3):269-76. <https://pubmed.ncbi.nlm.nih.gov/24630203/>.

11. Ma I, Arishenkoff S, Wiseman J, Desy J, et al. Internal medicine point-of-care ultrasound curriculum: consensus recommendations from the Canadian internal medicine ultrasound (CIMUS) group. *Journal of general internal medicine* 2017; 32(9):1052-1057. <https://doi.org/10.1007/s11606-017-4071-5>. <https://pubmed.ncbi.nlm.nih.gov/28497416/>.

# Real-time Point-of-care Ultrasound for the Diagnosis and Treatment of Testicular Torsion

Rahul V. Nene, MD, PhD; Rachna Subramony, MD; Michael Macias, MD; Colleen Campbell, MD; Amir Aminlari, MD

Department of Emergency Medicine, University of California, San Diego, San Diego, CA

## Abstract

**Background:** Testicular torsion is a surgical emergency that needs prompt diagnosis and treatment. Point-of-Care ultrasound (POCUS) can not only establish the diagnosis but also guide the Emergency Physician in evaluating the response to manual detorsion. **Case Report:** We describe the case of a 13-year-old male who presented with acute scrotal pain. We demonstrate how bedside ultrasound was used to make the diagnosis of testicular torsion, guide the technique for manual detorsion, and confirm adequate return of blood flow. Our case illustrates the ease with which POCUS can be used in real time to diagnose and treat organ-threatening pathology, but more importantly, it shows how real-time POCUS was used to detorse a testicle that was refractory to the standard detorsion technique. **Conclusion:** The acute scrotum is a time-sensitive presentation and if testicular torsion is present, the diagnosis should be made as soon as possible. Many Emergency Departments do not have 24-hour coverage of ultrasound technicians, which would delay the diagnosis and treatment. Moreover, when manual detorsion is attempted, it often does not work because the testicle may need more than the standard 180 degree medial to lateral rotation. POCUS provides real-time analysis of return of blood flow and can thus guide further rotation, or opposite direction rotation, as needed.

## Introduction

Testicular torsion is a surgical emergency with a yearly incidence of 3.8 per 100,000 males under the age of 18 [1]. The morbidity associated with testicular torsion is significant as 42% of surgeries result in orchiectomy [1]. However, testicular salvage rates are 90% to 100% if intervention is performed within 6 hours of symptom onset [2]. Thus, prompt diagnosis and treatment are critical in preventing testicular ischemic damage or necrosis.

Pre-operative manual detorsion is the fastest way to restore blood flow to the scrotum. This maneuver involves the physical rotation of the affected testicle in the opposite direction of the torsion, most commonly medial to lateral ("open book"). Manual detorsion can improve testicular salvage, however there is wide variation in the reported success of this strategy (26-95% successful) [3-6]. Success of manual detorsion can be complicated by unclear direction and degree of cord rotation [4]. Point-of-care ultrasound (POCUS) can be used by emergency physicians to detect testicular torsion. POCUS has a high sensitivity and specificity in the diagnosis of testicular torsion and its implementation in the work-up for acute scrotal pain has been reported to decrease the time to intervention [7-9]. High accuracy in determining direction of cord twist by ultrasound has also been reported [10]. Here we report the use of point-of-care ultrasound (POCUS) to guide manual detorsion.

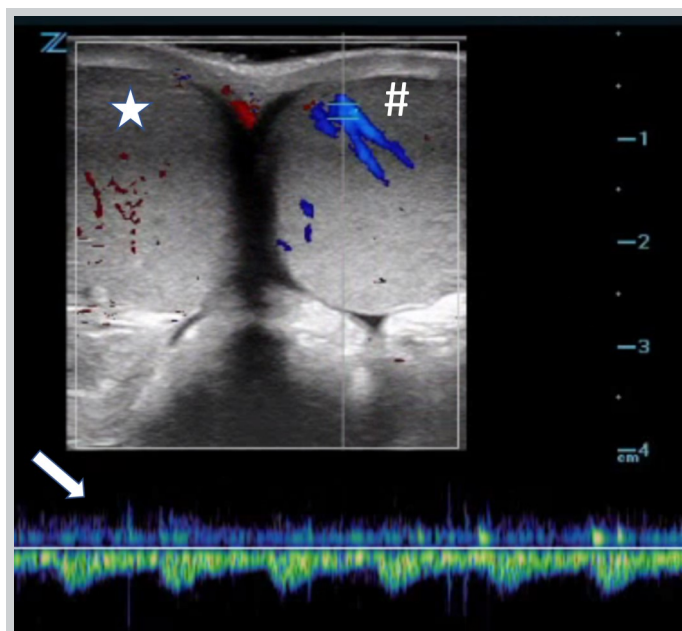


Figure 1. Point-of-care testicular ultrasound using doppler ultrasound imaging - Appropriate flow is demonstrated to the left testicle (#) indicated by color signal and arterial waveform on pulse wave doppler (arrow). No consistent color signal is appreciated over the right testicle (star), confirming the diagnosis of testicular torsion.

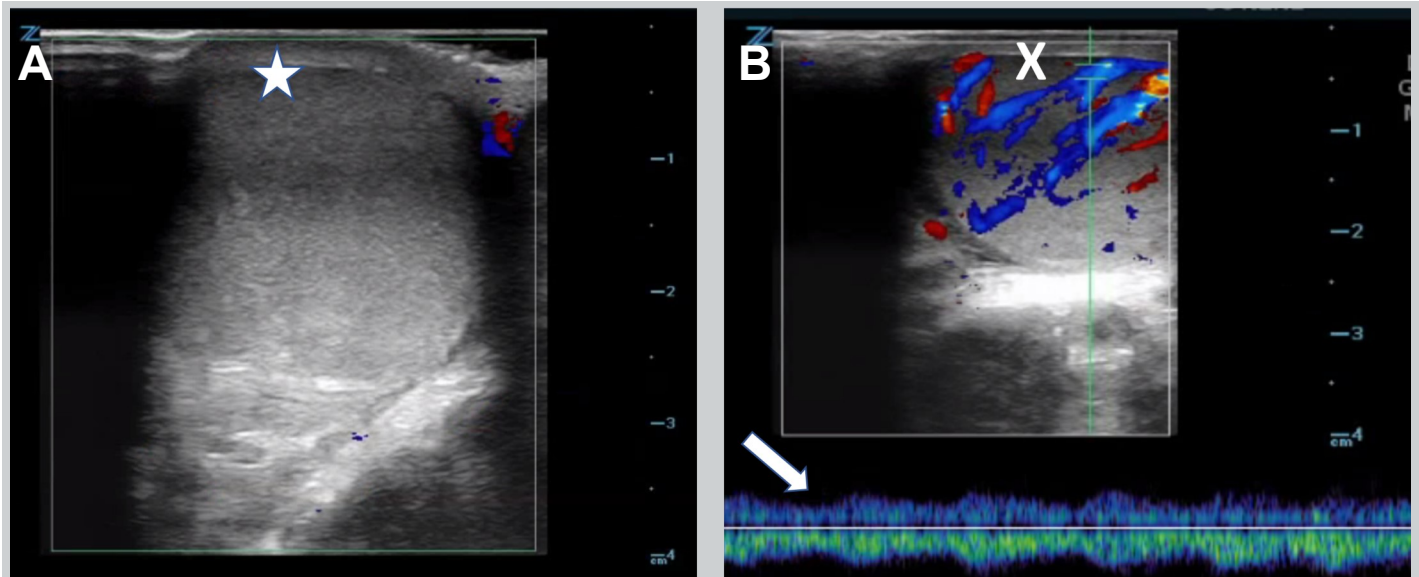


Figure 2. Doppler ultrasound imaging of right testicle during attempted detorsion. A) There was still absence of blood flow after initial detorsion attempt demonstrated by lack of color signal over the right testicle (star). B) After additional detorsion, color signal is now visible over the right testicle (X) and return of arterial waveform on pulse wave doppler (arrow), indicating restoration of blood flow.

### Case Presentation

A 13-year-old healthy male presented to the emergency department with acute onset of atraumatic right testicular pain 2 hours prior to arrival. He was afebrile and hemodynamically stable. Genital exam was remarkable for a firm high-riding right testicle, which was diffusely tender to palpation without overlying skin changes. Point-of-care ultrasound (POCUS) was performed using a high-frequency linear probe, which was placed in the transverse axis along the scrotum to obtain an image where both testicles are visible side by side (Figure 1). Color and pulse-wave doppler were used to evaluate testicular blood flow, demonstrating lack of flow to the right testicle, confirming the diagnosis of acute testicular torsion.

Manual detorsion was then attempted, initially by twisting the right testicle medial-to-lateral on the vascular pedicle 180 degrees. Bedside ultrasound was used to reevaluate the testicle and it continued to demonstrate a lack of flow (Figure 2A). The testicle was then rotated an additional 90 degrees, after which the patient had immediate relief of his pain and the testicle no longer felt as firm. Bedside ultrasound confirmed return of blood flow to the testicle (Figure 2B). The urology service was consulted, and the patient was taken to the operating room for emergent orchiopexy.

### Discussion

Testicular torsion is a surgical emergency and prompt diagnosis and treatment is necessary for testicular

salvage [11]. Classic exam findings include high-riding testis with profound swelling, tenderness, and loss of the cremasteric reflex. POCUS can help to rapidly make this diagnosis. Characteristic findings include loss of visual color flow to the affected testicle, spectral Doppler showing a high resistance arterial pattern, heterogeneous echotexture and enlargement of the affected testis, and the “whirlpool sign” with visible twisting of the spermatic cord [12]. Manual detorsion can be attempted by “opening the book” with medial-to-lateral rotation. However, this is not always effective, as further rotation, or even rotation in the opposite direction may be required to effectively detorse the testis. Real time ultrasound can be used to assess for improvement in flow during the procedure, specifically by guiding rotation degree and direction.

The diagnostic accuracy of POCUS for testicular torsion when performed by emergency physicians is 95% sensitive and 94% specific [8]. It has also been shown to be accurate for detecting torsion in children when performed by pediatric emergency physicians [7]. Despite the fact that POCUS is listed in the “Model of the Clinical Practice of Emergency Medicine as an integral diagnostic procedure,” the exact method and applications differ from program to program and the required “didactic, hands-on, and experiential components” of emergency ultrasound are not specifically outlined by the Residency Review Committee for Emergency Medicine (RRC-EM) or any single sponsoring group [13]. This leads to a variation in experience and knowledge with image acquisition and interpretation by emergency physicians, however studies have shown that it can be taught to emergency

physicians using a condensed program [14]. Despite adequate training, it is important to be aware of the pitfalls when performing POC testicular ultrasound that could lead to a misdiagnosis. For example, the use of color doppler ultrasound can have false negatives, especially in the case of partial torsion when there is arterial flow present but no venous flow, so it is crucial to check for both arterial and venous flow when performing this study. In some cases, arterial flow may be present but may show a high-resistance pattern, which can be nondiagnostic. Therefore, it is important to always consult the urology service when the clinical presentation is concerning for torsion even with a negative ultrasound.

### Statement of ethics approval/consent

We attest that our institution does not require IRB approval for case reports or de-identified clinical images and that the appropriate consent for the use of these images has been obtained from the patient/legal guardian. All authors reviewed and assisted with revisions of the final manuscript. RVN takes responsibility for the manuscript as a whole.

**Financial Support:** None

### References

1. L. C. Zhao, T. B. Lautz, J. J. Meeks, and M. Maizels, "Pediatric Testicular Torsion Epidemiology Using a National Database: Incidence, Risk of Orchiectomy and Possible Measures Toward Improving the Quality of Care," *J. Urol.*, vol. 186, no. 5, pp. 2009–2013, Nov. 2011, doi: 10.1016/j.juro.2011.07.024.
2. A. O. Ciftci, M. E. Şenocak, F. Cahit Tanyel, and N. Büyükpamukçu, "Clinical Predictors for Differential Diagnosis of Acute Scrotum," *Eur. J. Pediatr. Surg.*, vol. 14, no. 5, pp. 333–338, Oct. 2004, doi: 10.1055/s-2004-821210.
3. A. C. Dias Filho, R. Oliveira Rodrigues, C. L. Z. Riccetto, and P. G. Oliveira, "Improving Organ Salvage in Testicular Torsion: Comparative Study of Patients Undergoing vs Not Undergoing Preoperative Manual Detorsion," *J. Urol.*, vol. 197, no. 3 Part 1, pp. 811–817, Mar. 2017, doi: 10.1016/j.juro.2016.09.087.
4. S. Vasconcelos-Castro, B. Flor-de-Lima, J. M. Campos, and M. Soares-Oliveira, "Manual detorsion in testicular torsion: 5 years of experience at a single center," *J. Pediatr. Surg.*, vol. 55, no. 12, pp. 2728–2731, Dec. 2020, doi: 10.1016/j.jpedsurg.2020.02.026.
5. A. Demirbas et al., "Should manual detorsion be a routine part of treatment in testicular torsion?," *BMC Urol.*, vol. 17, no. 1, p. 84, Dec. 2017, doi: 10.1186/s12894-017-0276-5.
6. L. Garel, J. Dubois, G. Azzie, D. Filiatrault, A. Grignon, and S. Yazbeck, "Preoperative manual detorsion of the spermatic cord with Doppler ultrasound monitoring in patients with intravaginal acute testicular torsion," *Pediatr. Radiol.*, vol. 30, no. 1, pp. 41–44, Jan. 2000, doi: 10.1007/s002470050012.
7. N. Friedman et al., "Accuracy of point-of-care ultrasound by pediatric emergency physicians for testicular torsion," *J. Pediatr. Urol.*, vol. 15, no. 6, pp. 608.e1–608.e6, Dec. 2019, doi: 10.1016/j.jpuro.2019.07.003.
8. M. Blaivas, P. Sierzenski, and M. Lambert, "Emergency Evaluation of Patients Presenting with Acute Scrotum Using Bedside Ultrasonography," *Acad. Emerg. Med.*, vol. 8, no. 1, pp. 90–93, Jan. 2001, doi: 10.1111/j.1553-2712.2001.tb00563.x.
9. M. Blaivas, M. Batts, and M. Lambert, "Ultrasonographic diagnosis of testicular torsion by emergency physicians," *Am. J. Emerg. Med.*, vol. 18, no. 2, pp. 198–200, Mar. 2000, doi: 10.1016/S0735-6757(00)90020-

2.

10. T. Hosokawa et al., "Diagnostic Accuracy of Ultrasound for the Directionality of Testicular Rotation and the Degree of Spermatic Cord Twist in Pediatric Patients With Testicular Torsion," *J. Ultrasound Med.*, vol. 39, no. 1, pp. 119–126, Jan. 2020, doi: 10.1002/jum.15084.
11. V. J. Sharp, K. Kieran, and A. M. Arlen, "Testicular torsion: diagnosis, evaluation, and management," *Am. Fam. Physician*, vol. 88, no. 12, pp. 835–40, Dec. 2013, [Online]. Available: <http://www.ncbi.nlm.nih.gov/pubmed/24364548>.
12. A. N. Bandarkar and A. R. Blask, "Testicular torsion with preserved flow: key sonographic features and value-added approach to diagnosis," *Pediatr. Radiol.*, vol. 48, no. 5, pp. 735–744, 2018, doi: 10.1007/s00247-018-4093-0.
13. M. B. Heller et al., "Residency Training in Emergency Ultrasound: Fulfilling the Mandate," *Acad. Emerg. Med.*, vol. 9, no. 8, pp. 835–839, Aug. 2002, doi: 10.1111/j.1553-2712.2002.tb02174.x.
14. L. Stringer et al., "Point-of-care ultrasonography for the diagnosis of testicular torsion: a practical resident curriculum," *Can. J. Surg.*, vol. 64, no. 2, Mar. 2021, doi: 10.1503/cjs.019119.



# Diagnosis of Central Retinal Artery Occlusion in the Emergency Department Using POCUS: A Case Series

Nicholas Cozzi, MD, MBA; Kendall Stevens, BS; Yeoshina Pillay, MD; David Moore MD; Matthew Flannigan, DO; Mariah Barnes, MD; Matthew Singh, MD; Melisa Gargica, MD; Christian Kolacki, MD; Jennifer Bach, DO; Dale McNinch, MD; Drue Orwig, DO; Jeffrey Jones, MD

Spectrum Health| Michigan State University College of Human Medicine, Grand Rapids, MI

## Abstract

**Introduction:** Central Retinal Artery Occlusion is a cause of vision loss that warrants emergent evaluation. Ocular Point of Care Ultrasound (POCUS) is a non-invasive, inexpensive, and rapid modality to establish diagnosis with reduced time to consultation and treatment. **Methods:** This was a retrospective case series of patients evaluated at seven hospitals with diagnosis of CRAO over a two-year period. All patients underwent ocular POCUS performed by an emergency medicine clinician. **Results:** Nine patients were evaluated with mean vision loss of 21 hours. Overall, 88% of patients were diagnosed with CRAO, 75% possessing US confirmed retrobulbar spot sign (RBBS), and 38% confirmed diagnosis with fundoscopy. **Conclusion:** Ocular POCUS is an examination all emergency medicine clinicians should be able to perform. A rapid diagnosis of CRAO provides opportunity for vision improvement with initiation of treatment. The lack of guidelines for treatment of CRAO represents an opportunity for a multi-specialty collaboration to develop a diagnostic and treatment algorithm.

## Introduction

Painless vision loss represents 1.75% of annual emergency department (ED) visits [1,2] but can suggest not only an acute threat to vision, but also significant systemic pathology. The long term morbidity associated with vision impairment cannot be understated; it intercalates with every facet of a person's daily life which include professional and personal. Central Retinal Artery Occlusion, CRAO, is a common cause of painless vision loss that warrants prompt recognition and expert consultation. Thromboembolic disease related to cardiovascular or stroke risk factors [3], rheumatologic disease such as giant cell arteritis, or pathology localized to the eye can all present in a similar fashion [4]. The Retrobulbar spot sign, or Hollenhorst sign/plaque was first described in 1992 consists of a bright echogenic white spot visualized in the central retinal artery in ocular POCUS and is consistent with cholesterol deposits reflective of thromboembolic disease [5,6].

For many causes of acute painless vision loss, dilated fundoscopic exam is considered the gold standard for diagnosis; however, this can be a challenging exam in some patients, especially in resource-limited settings without expert consultation available. It has previously been shown that point-of-care ultrasound (POCUS) can be used to characterize and evaluate both arterial and venous flow in cases of retinal vessel compromise using color Doppler imaging,[7,8] and to directly visualize retinal

artery thrombus. Rapid diagnosis in the emergency department can decrease time to treatment, and increase the patient's chances of regaining vision [4].

## Methods

This study is an IRB-exempt case series of all patients seen at seven participating hospitals in West Michigan from July 2018 to July 2021 with a diagnosis of CRAO. All physicians have training and experience with POCUS as a means of rapid eye examination. These patients underwent POCUS imaging performed with prompt ophthalmology evaluation within 72 hours to be eligible for this study. Patient demographics, chief complaints, comorbidity, other radiographic studies, treatment in the ED, final disposition, and complications were obtained from the medical records using standardized abstraction forms. The emergency departments in all the participating hospitals are staffed by board-certified or board-eligible emergency physicians. A Zonare L10-5 linear array probe was to evaluate the eye in two perpendicular planes while the patient was supine with the head of the bed elevated thirty degrees. Ultrasound gel was used and slight pressure applied for visualization. Patient instructed to look side to side/up and down as this accentuates movement of retinal and vitreous pathology. Ultrasound exams were stored in QPath (a quality assurance and imaging documentation software) and used to confirm diagnostic accuracy through review by an emergency ultrasound fellowship trained physician.

We were particularly interested in the feasibility and accuracy of EM providers using POCUS to diagnose acute CRAO. For the purposes of this study, feasibility will be defined as the ease of making a diagnosis and the accuracy will be based on image quality, retention of an adequate number of views to yield a diagnosis, and specificity when compared to a dilated fundoscopic exam by an ophthalmologist.

## Results

Nine patients were seen at affiliated hospitals during the study period. The mean age was 64 +/- 19 SD; 55% were male. Overall, 88% of patients had risk factors for embolic occlusive disease, pre existing coronary arterial disease, peripheral vascular disease, carotid arterial disease, and/or atrial fibrillation. The average duration of monocular painless vision loss consisted of 21 hours when averaged over the 9 patients. However, when excluding two patients who had vision loss for greater than three days, the mean duration of vision loss for the remaining seven patients was 3 hours. All patients underwent ocular POCUS performed by an emergency medicine physician with 78% (7/9) patients having a POCUS confirmed, retrobulbar spot sign (RBBS; Figure 1, online Video S1). However, 38% of patients had ophthalmology confirmed diagnosis with fundoscopic examination. In terms of treatment, 67% of our case series underwent hyperbaric oxygen therapy (HBOT) with mean sessions being 3.6 at 2.8 atm. Of those patients undergoing HBOT, 40% had subjective improvement in their vision via Snellen Chart. One patient who was only able to recognize light and color improved where now this patient recognized hand motion. One patient underwent intra-arterial Tissue Plasminogen Activator (TPA) and notably, this was a teenager who did not recover vision.

## Discussion

Painless vision loss is a common emergency department complaint that is associated with high morbidity. Ocular POCUS is an inexpensive, non-invasive, and a rapid diagnostic modality emergency physicians can perform at the bedside to assess painless vision loss. Ocular POCUS is also useful for visualization of retinal detachment (RD), vitreous hemorrhage (VH), and posterior vitreous hemorrhage (PVH) which is displayed in table form. In addition, ocular ultrasound can assist in identifying optic nerve sheath edema due to increased intracranial pressure of greater than 20cm (sensitivity of 88%, specificity of 93%) [8]. Ocular POCUS is a relatively new modality and one study comments on missed diagnosis of patients with CRAO due to providers not having the required training to perform this diagnostic maneuver. Retrobulbar spot sign is found in a subset of CRAO patients and is associated with a thromboembolic etiology. Our research indicates that RBBS may be

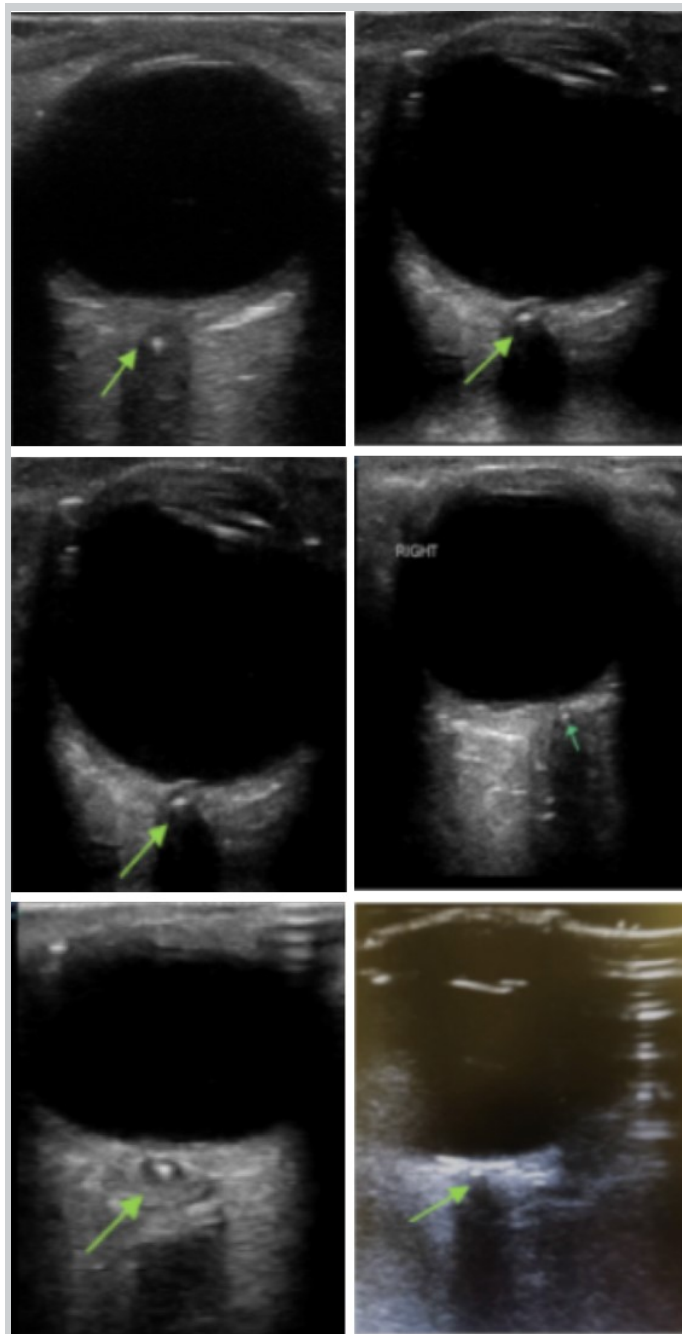


Figure 1. Retrobulbar Spot Sign (Hollenhorst sign/ plaque). The above green arrow refers to six distinct patients with ocular-POCUS confirmed Retrobulbar spot sign (RBBS), also called the Hollenhorst sign/ plaque, located in the central retinal artery.

sensitive in diagnosing CRAO, but not as specific given only 38% of our subset had CRAO confirmed via ophthalmology. An additional finding consistent with CRAO is evaluation of the arterial doppler signal to confirm dampened waveforms consistent with flow-limiting occlusion. The visualization of retrobulbar spot sign is associated with CRAO with two studies correlating the association to approximately 59% [5,8,9]. Early

visualization of RBBS (within 12 hours) and subsequent diagnosis of CRAO would reduce the time to diagnosis and HBOT. One study demonstrated that HBOT-treated non-arteritic CRAO patients were able to achieve an improvement of three lines on the Snellen visual acuity scale (38% vs. 17%,  $p=0.06$ ,) [10].

## Conclusion

Ocular POCUS is a non-invasive examination all emergency medicine clinicians should be able to perform. A rapid diagnosis of CRAO has the opportunity to reduce the time to treatment with the best chance for vision improvement. The lack of robust guidelines for the treatment of CRAO represents an opportunity for a multi-specialty collaboration to develop a structured diagnostic and treatment algorithm.

## Statement of ethics approval/consent

### Approval

All authors approved the version to be published and agreed to be accountable for all aspects of the work.

### Funding

The authors do not have any funding source.

### Conflict of interest

The authors do not have any conflicts of interest to report.

## References

1. Channa R, Zafar SN, Canner JK, et al. Epidemiology of Eye-Related Emergency Department Visits. *JAMA Ophthalmol*. 2016;134(3):312–319. doi:10.1001/jamaophthalmol.2015.5778
2. The Latest Emergency Department Utilization Numbers Are In. ACEP Now. <https://www.acepnow.com/article/the-latest-emergency-department-utilization-numbers-are-in/#:~:text=ED%20visit%20estimates%20increased%20from,estimates%20appear%20in%20Table%201>. Accessed October 10, 2021.
3. Schmidt D, Hetzel A, Geibel-Zehender A, et al. Systemic diseases in non-inflammatory branch and central retinal artery occlusion-an overview of 416 patients. *Eur J Med Res*. 2007;12(12):595–603.
4. Beran DI, Murphy-Lavoie H. Acute, painless vision loss. *J La State Med Soc*. 2009;161(4):214–26.
5. Smith A, Wilbert C, Ferre R. Using the Retrobulbar Spot Sign to Assist in Diagnosis and Management of Central Retinal Artery Occlusions. *American Institute of Ultrasound in Medicine. J Ultrasound Med* 2020; 39: 197-202.
6. Sergott RC, Flaharty PM, Lieb WE Jr, et al. Color Doppler imaging identifies four syndromes of the retrobulbar circulation in patients with amaurosis fugax and central retinal artery occlusions. *Trans Am Ophthalmol Soc* 1992; 90:383–401.
7. Foroozan R, Savino PJ, Sergott RC. Embolic central retinal artery occlusion detected by orbital color Doppler imaging. *Ophthalmology*. 2002;109(4):744–7.
8. Stoner-Duncan B, Morris SC. Early Identification of Central Retinal Artery Occlusion Using Point-of-care Ultrasound. *Clin Pract Cases Emerg Med*. 2019 Feb; 3(1): 13–15.
9. Nedelman M, Graef M, Weinand F, et al. Retrobulbar Spot Sign Predicts Thrombolytic Treatment Effects and Etiology in Central Retinal Artery Occlusion. *Stroke*. June 25, 2015.

10. Menzel-Severing J, Siekmann U, Weinberger A, et al. Early Hyperbaric Oxygen Treatment for Non-Arteritic Central Retinal Arterial Occlusion. *American Journal of Ophthalmology*. October 11, 2011.

11. Blaivas M, Theodoro D, Sierzenski P. et. al. A study of bedside ocular ultrasonography in the emergency department. *Acad Emerg Med*. 2002;9(8):791-9.

# How Point-of-Care Ultrasound Led to a Diagnosis of May-Thurner Syndrome

Daniel L. Belkin, BFA<sup>1\*</sup>; Mitchell D. Belkin, BA<sup>2\*</sup>; Maedeh Ashrafi, MD<sup>1,3</sup>; Charan Vegivinti, MD<sup>1,3</sup>; Yung-Hsien Wang, MD<sup>1,3</sup>; Leonidas Palaiodimos, MD<sup>1,3</sup>

(1) Albert Einstein College of Medicine, Bronx, New York 10461

(2) University of Maryland School of Medicine, Baltimore, Maryland 21201

(3) Department of Medicine, Jacobi Medical Center, NYC H+H, Bronx, New York 10461

\*Authors contributed equally

## Abstract

A 65-year-old man with a history of a left-sided inguinal hernia presented with three days of left-sided groin pain worsened with exertion and fatigue. The patient was afebrile but tachycardic, and physical examination revealed a tender, erythematous immobile bulge in his left groin. Laboratory studies revealed leukocytosis. Lymphadenopathy secondary to infectious or inflammatory etiology was suspected. However, point-of-care ultrasound (POCUS) identified extensive deep vein thrombosis (DVT) of the lower left limb. Follow-up imaging revealed this to be secondary to May-Thurner syndrome, a mechanical compression of an ilio caval vein against the lumbar vertebrae by a common iliac artery. This report demonstrates how POCUS can be used to identify lower extremity DVT, thereby expediting diagnosis and treatment and potentially preventing complications.

## Introduction

May-Thurner syndrome (MTS) is the mechanical compression of an ilio caval vein, most commonly the left iliac vein, against the lumbar vertebrae by the arterial system, most commonly the right common iliac artery. Although it may be asymptomatic, this uncommon condition places individuals at risk for extensive deep vein thrombosis (DVT) of the left lower limb. Our case demonstrates how clinicians utilized point-of-care ultrasound (POCUS) to diagnose extensive left lower extremity DVT, thereby expediting the diagnosis and treatment of MTS.

## Case presentation

A 65-year-old man with a history of active tobacco use (40 pack-year) and left-sided inguinal hernia presented to the emergency room with fatigue and anorexia associated with left-sided groin pain that was aggravated by exertion. The symptoms started three days prior to presentation. The patient denied any other symptoms in open- and closed-ended questions. He reported mild intermittent left-sided groin pain attributable to his known inguinal hernia. However, he denied similar symptoms in the past. He did not take any medications, denied sexual activity for the past year, and denied toxic habits other

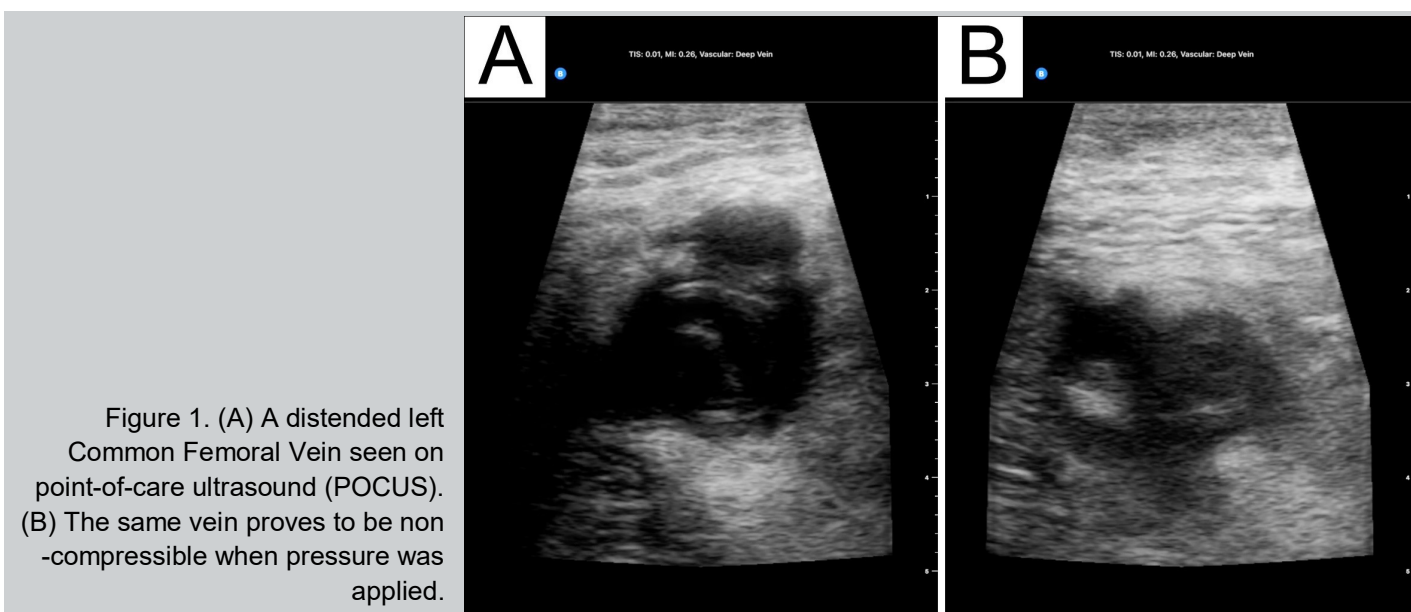



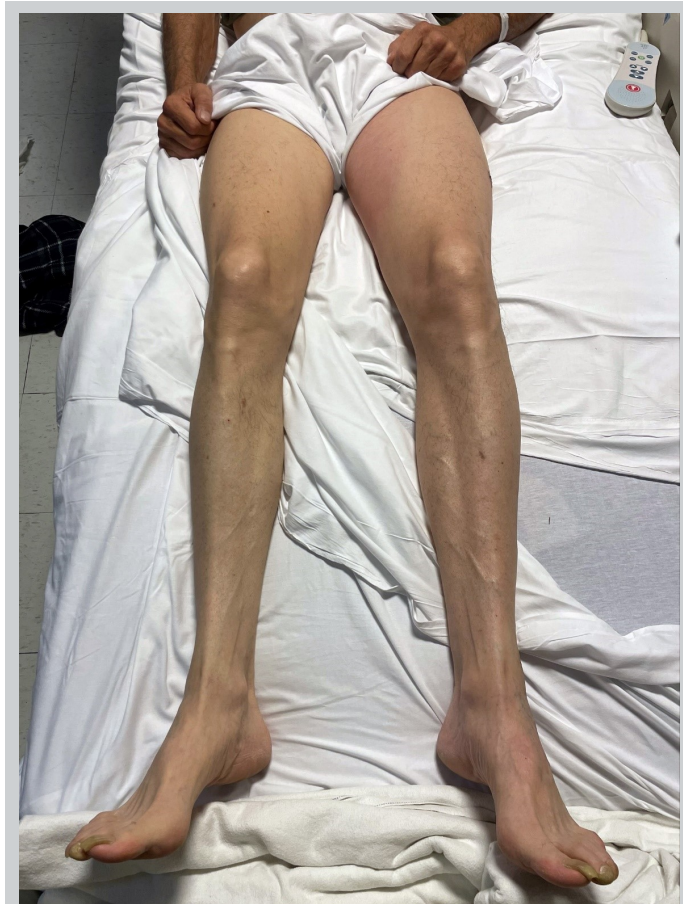


Figure 2. Picture of the patient's lower extremities showing no significant edema, erythema or asymmetry.

than tobacco use. He worked as a building superintendent and described himself as active and healthy. His body mass index was 24 kg/m<sup>2</sup>.

On presentation, the patient was afebrile, heart rate was 111 beats per minute, respiratory rate was 17, blood pressure was 130/80 mm Hg, and SpO<sub>2</sub> was 97% on ambient air. The physical examination was remarkable only for a small erythematous, palpable, tender, well-defined, immobile bulge in his left groin surrounded by mild erythema, which spread to his left inner thigh in the first two days of hospital stay. The rest of the physical examination was unremarkable. The laboratory work-up was remarkable for neutrophilic leukocytosis (WBC 14.83/nL) and significantly elevated C-reactive protein (CRP 230.3 mg/L). Hemoglobin, platelet count, basic coagulation panel, and comprehensive metabolic panel were unremarkable.

At this point, the admitting medicine team was considering an infectious or inflammatory etiology and believed the palpable lesion in the left groin to be secondary to lymphadenopathy rather than an inguinal hernia as the patient believed. A point-of-care ultrasound

examination was performed to visualize the enlarged lymph nodes. Surprisingly, a large echogenic thrombus was seen extending from the common femoral vein (CFV) to the mid-thigh. The CFV and femoral vein (FV) were distended and non-compressible (Figure 1, online Video S1).

This finding came as a surprise as no lower extremity edema was noted on physical exam (Figure 2). Up until this visualization with point-of-care ultrasound, DVT had not been in the working differential diagnosis.

A vascular lab performed duplex ultrasound was ordered to confirm our bedside findings and revealed extensive DVT in the left lower extremity including the distal external iliac vein, CFV, proximal deep femoral vein, proximal-to-distal FV, as well as acute superficial venous thrombosis in the great saphenous vein at the level of the saphenous-femoral junction and proximal thigh (Figure 3).

In the meantime, d-dimer concentrations were found to be 1840 ng/mL and therapeutic anticoagulation with Enoxaparin 1 mg/kg every 12 hours was initiated. Computed tomography (CT) of the chest, abdomen, and pelvis with contrast revealed findings consistent with May-Thurner syndrome, with the left and right common iliac arteries compressing the left iliac vein proximal to the clot (Figure 4).

Vascular surgery was consulted and the patient underwent localized thrombolysis, thrombectomy and stent placement in the left iliac vein. The patient tolerated the procedure and did not have any complications. His symptoms, including fatigue and anorexia, gradually resolved. CRP concentrations declined to 115.4 mg/L, and the patient was discharged on post-op day 3 on Aspirin, Clopidogrel, and Apixaban with vascular surgery follow-up and age-appropriate cancer screening including colonoscopy. Of note, CT of the chest, abdomen, and pelvis did not reveal any evidence of malignancy, and prostatic-specific antigen (PSA) concentration was unremarkable. Thrombophilia work-up was not indicated given the patient's age, the absence of a history of thromboembolic episodes, and the detection of an anatomic risk factor for thrombosis, MTS.

## Discussion

May-Thurner syndrome is estimated to cause 2-5% of all DVTs [1]. MTS is most common in patients between 18 and 50 years old, with women being five times more likely than men to suffer from the condition [2]. MTS patients that have additional risk factors such as recent surgery, pregnancy, oral contraceptive pill use, and malignancy are more likely to form blood clots and develop DVT [2]. Furthermore, patients with asymptomatic MTS who also have hypercoagulable disorders, infection, or dehydration

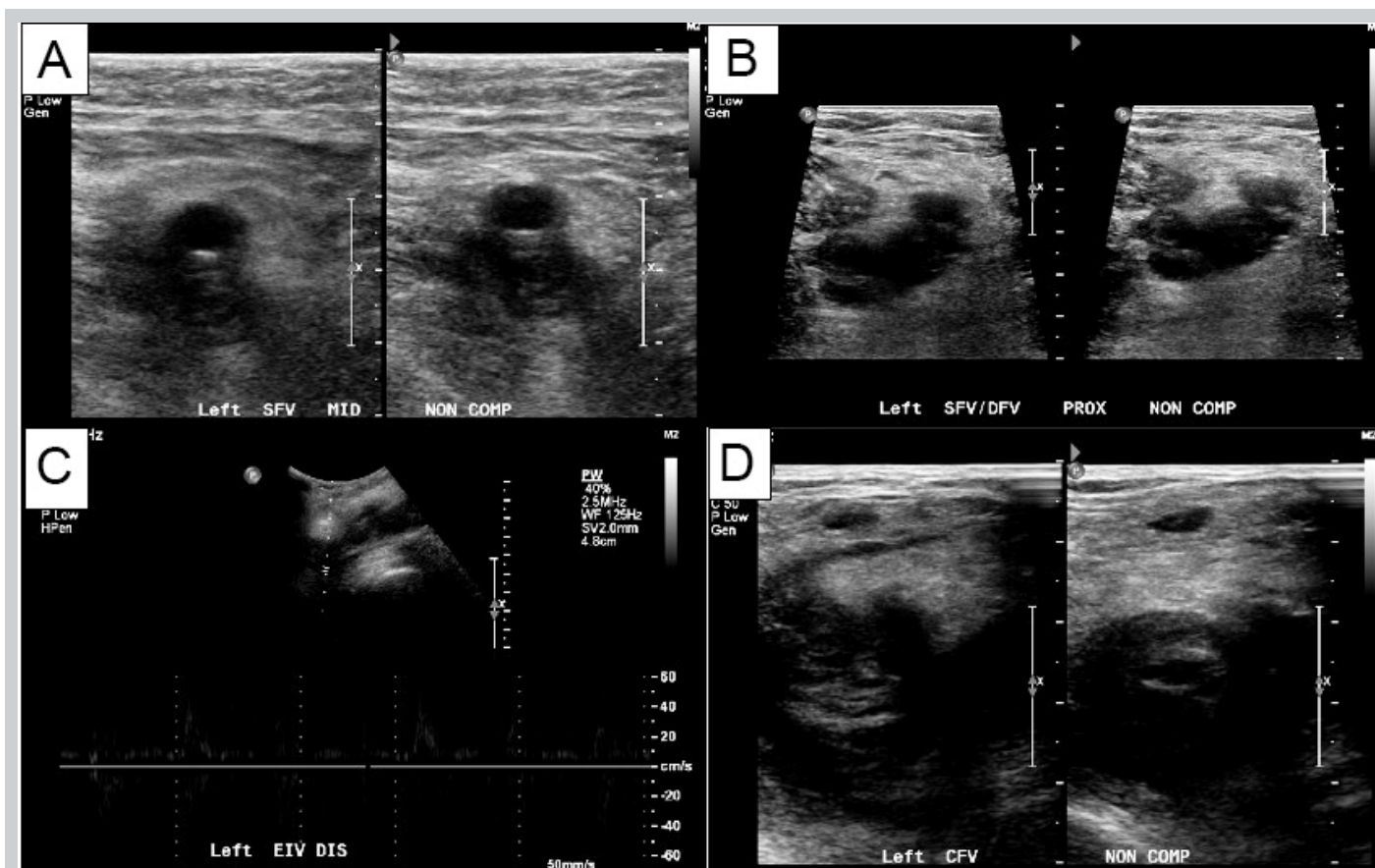


Figure 3. A vascular-performed duplex ultrasound revealed acute non-compressible deep vein thrombosis in the left lower extremity involving (A) the left superficial femoral vein; (B) the left deep femoral vein; (C) the left external iliac vein; (D) the left common femoral vein.

are more likely to develop a DVT [2].

The gold standard to diagnose MTS is CT venography with transvenous pressure measurements. However, this invasive procedure entails potential complications, including phlebitis; thus, other imaging modalities are first line, including ultrasound doppler, which is an easy and inexpensive screening modality [1, 3]. On ultrasound doppler, MTS can be diagnosed by identifying elevated blood velocity in the common iliac vein, but this requires significant technical expertise [3, 4]. As a result, an MTS diagnosis even in patients with symptomatic DVT may be missed. To confirm the diagnosis of MTS, other imaging modalities such as CT venography, magnetic resonance imaging (MRI), or CT abdomen and pelvis with contrast may be performed [3].

Treatment of thrombosis in the setting of MTS involves catheter-delivered thrombolytics and percutaneous mechanical thrombectomy, either with or without angioplasty and stent placement [1]. Due to the pulsatile nature of mechanical arterial obstruction, MTS responds poorly to conservative management with anticoagulation alone [1]. Failure to treat MTS quickly could lead to post-

thrombotic syndrome (PTS), which is thought to occur as a result of valvular incompetence and venous hypertension and leads to leg swelling and chronic skin changes such as hyperpigmentation, induration, and ulceration [5]. Meta-analysis has demonstrated the superiority of catheter-directed thrombolysis when compared to anticoagulation alone for the prevention and treatment of PTS [6].

Our case demonstrates how POCUS can help identify extensive DVT in an individual without classic signs of DVT. POCUS enables clinicians to visualize the anatomy and pathology of the groin, including the hip, anterior hip musculature, the inguinal lymph nodes, and inguinal hernias, which can be seen with significant sensitivity and specificity [7]. Of note, POCUS can assist with identification of lower extremity proximal DVT and as such it is now routinely used in the ED, ICU, and other healthcare settings [8]. Studies and meta-analyses which use POCUS to evaluate for DVT have an estimated sensitivity and specificity in the 90-100% range [8]. As such, POCUS is a strong clinical tool that ought to be used more frequently by clinicians.

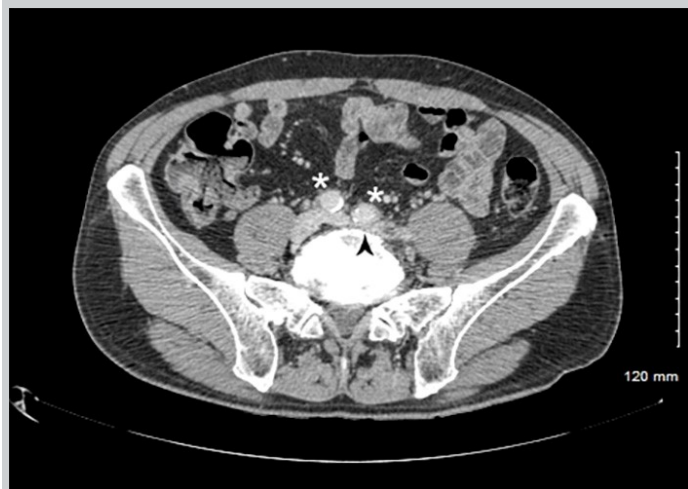

Figure 4 Contrast-enhanced CT showed that the left iliac vein (arrowhead) was compressed by the left and right common iliac arteries (asterisk), consistent with a diagnosis of May-Thurner syndrome.

6. Mastoris, I., et al., *Catheter-directed thrombolysis vs. anticoagulation for the prevention and treatment of post-thrombotic syndrome in deep vein thrombosis: An updated systematic review and meta-analysis of randomized trials*. *Phlebology*, 2019. **34**(10): p. 675-682.

7. Jacobson, J.A., V. Khoury, and C.J. Brandon, *Ultrasound of the Groin: Techniques, Pathology, and Pitfalls*. *AJR Am J Roentgenol*, 2015. **205**(3): p. 513-23.

8. Varrias, D., et al., *The Use of Point-of-Care Ultrasound (POCUS) in the Diagnosis of Deep Vein Thrombosis*. 2021. **10**(17): p. 3903.

For our case who presented without typical findings and risk factors for DVT, the use of POCUS completely altered our differential diagnosis and led to prompt identification and treatment of MTS. The ease of access to POCUS and its efficacy at identifying extensive DVT was instrumental in the proper care of this patient.

### Conclusion

Physicians should consider lower extremity DVT in groin-related presentations, even without classic signs of DVT. Point-of-care ultrasound is an easily accessible and can be a first-line screening tool in the identification of extensive DVT.

**Conflict of interest:** none

**Funding:** none

**Patient consent:** written

### References

1. Harbin, M.M. and P.L. Lutsey, *May-Thurner syndrome: History of understanding and need for defining population prevalence*. *J Thromb Haemost*, 2020. **18**(3): p. 534-542.
2. Liddell, R.P. and N.S. Evans, *May-Thurner syndrome*. 2018. **23**(5): p. 493-496.
3. Knuttinen, M.G., et al., *May-Thurner: diagnosis and endovascular management*. *Cardiovasc Diagn Ther*, 2017. **7**(Suppl 3): p. S159-s164.
4. Metzger, P.B., et al., *Criteria for detecting significant chronic iliac venous obstructions with duplex ultrasound*. *J Vasc Surg Venous Lymphat Disord*, 2016. **4**(1): p. 18-27.
5. Evans, N.S. and E.V. Ratchford, *Vascular Disease Patient Information Page: The post-thrombotic syndrome*. 2014. **19**(4): p. 331-333.



# Taking the Pulse of POCUS: The State of Point-of-Care Ultrasound at a Pediatric Tertiary Care Hospital

Peter Gutierrez, MD<sup>1,2</sup>; Tal Berkowitz, MD<sup>1,2</sup>; Lekha Shah, MD<sup>1,2</sup>; Stephanie G. Cohen, MD<sup>1,2</sup>

(1) Emory University School of Medicine, Atlanta, GA

(2) Children's Healthcare of Atlanta, Atlanta, GA

## Abstract

We aim to quantify and categorize point-of-care ultrasound (POCUS) usage by pediatric practitioners and trainees at our tertiary care center, and assess the degree of interest from pediatric residents, fellows, and program leaders for integrating POCUS into their training. Data was collected via online survey, evaluating the current use of POCUS in clinical decision making, desire for further formal training, and opinions on the importance of POCUS to future clinical practice. In total, 14 program directors/assistant program directors (PD/APDs) representing 10 of 15 training programs, 30 of 95 fellows representing 9 of 15 fellowships, and 32 of 82 residents responded. From PD/APDs, only 2 of the programs reported active use POCUS for clinical decision making, but 13 of the fellows and 9 residents reported doing so. In regard to desire for a formal POCUS program, 30.8% of PD/APDs, 43.8% of fellows without current curricula, and 87.5% of residents were interested in participating in such a program. When considering specialty, some non-acute care-based PD/APDs and fellows at our institution felt that POCUS was important to future practice. Pediatric subspecialty PD/APDs and their fellows had divergent outlooks on the importance of POCUS in future practice. Finally, an overwhelming majority of residents at our institution expressed a desire to learn, and half believing it will be important to future practice. Based on the degree of interest, medicolegal considerations, and trajectory of patient care, pediatric residency and fellowship programs should strongly consider integrating POCUS education into their curricula.

## Background

Point-of-care ultrasound (POCUS), ultrasound both performed and interpreted by a clinician at the bedside and used to answer immediate questions or to perform procedures, is becoming an integral part of daily practice in many areas of medicine. Most published curricula exist in adult-focused specialties, including emergency medicine [1-3], internal/family medicine [4-7], critical care [8], general surgery [9], anesthesiology [10], and nephrology [11]. There are few similar publications in pediatric specialties, with pediatric emergency medicine and critical care being notable exceptions [12-15]. While POCUS is most consistently used in the acute care setting, it also has applications in the ambulatory and inpatient settings [16].

To our knowledge, there are no published reports of the degree of POCUS use in pediatric subspecialties. Currently, there are multiple pediatric subspecialties that have board content specifications that involve ultrasound, but the majority involve only knowing its indications or limitations (adolescent medicine, child abuse pediatrics, neonatology), interpretation of scans performed by technicians or radiologists (gastroenterology, plastic surgery), or have very limited applications (cardiology). Other subspecialties express only an awareness of the

modality (endocrinology, neurology/epileptology, neurosurgery). Pediatric emergency medicine (EM) is unique in that its board content specifications explicitly mentions POCUS [17-27]. In spite of this, multiple specialties at our institution report the use of POCUS in clinical decision-making, which prompted our inquiry. The primary purpose of this study is to quantify and categorize the use of POCUS by pediatric subspecialists across our large tertiary care academic pediatric hospital system. Secondary aims of this study were to assess the degree of interest in formal POCUS training and perceived importance to future clinical practice by pediatric trainees and their program leaders.

## Methods

Data from this study was collected via an online survey. One survey type was sent to the program directors and associate program directors (PDs/APDs) for the pediatric residency and pediatric fellowships at our institution. A separate, but similar, survey sent to the general pediatric residents and subspecialty fellows in training at our institution at the time of administration. Surveys listed demographics, training level, questions about current practice and future training interest in POCUS, and attitudes about the importance of POCUS in future clinical practice. Surveys were created in REDCAP and



disseminated via email. Results were de-identified and underwent descriptive statistical analysis upon completion of the study period. Current PD/APDs of general pediatrics or a pediatric subspecialty, general pediatric residents, or pediatric subspecialty fellows were included. There were no exclusion criteria. Data was compiled on secure SharePoint and REDCAP sites. Statistical analyses were performed using Microsoft Excel (Microsoft Excel for Mac 2019, Microsoft Corporation, Version 16.34), which included calculating percentages. This study was granted exemption from our institutional review board.

## Results

In total, 14 PDs/APDs responded to the survey, representing 10 of the 15 pediatric fellowship programs available at our institution. Respondents included representatives from endocrinology, cardiology, gastroenterology (GI), nephrology, allergy/immunology, hematology/oncology, rheumatology, neurology, neonatology, and critical care medicine (CCM). Only two of the respondents, a rheumatologist and a cardiologist, indicated that they personally perform point-of-care ultrasound scans for medical decision-making. The rheumatologist reporting using point-of-care (POC) musculoskeletal imaging, and the cardiologist reported using POC noncardiac thoracic imaging. Regarding the importance of POCUS in future practice of their specialty, four respondents indicated it was "important" and the remaining ten were either neutral or reported it was not important. Currently, only one program (CCM) reported having a current POCUS curriculum for their fellows. Of note, the program director for EM did not respond, but that specialty is known to have a formal curriculum for its fellows. Four of 13 respondents without a POCUS program, cardiology, nephrology, endocrinology, and neonatology, reported a desire to create a POCUS course for their fellows (Table 1).

Thirty out of 95 fellows representing 9 of 15 total fellowships responded to the survey. Regarding types of scans being performed for clinical decision making, thirteen respondents reported using POCUS clinically to some degree while 17 reported not using it at all. All applications except airway, thyroid, abdomen, and male genitourinary (GU) were reported as currently used. When CCM and EM fellows were removed, only cardiac, aorta, renal/bladder, MSK, soft tissue, and thoracic modalities were reported. Remaining reports were from cardiology fellows, except for one MSK respondent from an undeclared specialty. When asked what applications fellows wanted to learn, respondents from nine different specialties listed at least one application they felt would be beneficial to their practice. With regards to importance of POCUS to the future of their specialty, 16 of 30

responded "important" or "very important", while 14 responded neutral or not important. Currently, only critical care medicine, emergency medicine, and cardiology respondents reported having a POCUS curriculum. Of note, there were two respondents from cardiology, one of whom reported that their program had a formal POCUS curriculum, while other reported that there was not one. Of the 18 non-EM/CCM fellow respondents that are known to not have a POCUS curriculum, eight would like to start a program, including those from endocrinology, GI, hospitalist medicine, neonatology, two that did not report their training program, and the other respondent from cardiology (Table 2).

The survey administered to residents included 32 completed surveys from a possible 76 categorical general pediatric (GP) residents and 6 General Pediatric/Neurology (GP/N) residents, of which 17 came from GP, 3 from GP/N, and 12 unreported. Despite no formal training program, nine residents did report currently using a variety of POCUS modalities, most commonly soft tissue. When asked about which POCUS modalities they would like to learn, all modalities were mentioned by at least one resident, but the most common responses were extended focused assessment with sonography for trauma (eFAST), cardiac, MSK, soft tissue, and abdomen. Half of the residents reported POCUS is either "important" or "very important" to their future learning, while the other half felt it is either "not important" or are "neutral." (Table 3).

## Discussion

Within our institution there is currently formal POCUS training limited to two specialties, EM and CCM, with some formal teaching in cardiology in addition to their echocardiography training, but not an official POCUS curriculum.

Outside of EM, CCM, cardiology, and rheumatology, faculty did not have experience with POCUS, and most did not feel it is important for their fellows' education. However, there is indeed desire from a few subspecialists at our institution to create a formal curriculum for their fellows.

On the other hand, about half of subspecialty trainees reported that POCUS is an important part of their future education with fellows desiring a broader array of modalities to learn compared to residents. While currently the majority of POCUS is being performed by fellows in EM, CCM, and cardiology, fellows from a number of other specialties expressed a desire to learn at least one modality of POCUS, typically one specifically related to their field, for example a nephrology fellow desiring to learn renal/bladder US, and an endocrine fellow desiring to learn thyroid US. There appeared to be a considerable

Table 1. Responses from PD/APDs to POCUS Survey

Question	Response Choice	Response No. (%)	Specialty
Number of respondents		14	
Program Directors		7 of 14 (50%)	
Program represented	Allergy/immunology (A/I)	1	
	Cardiology	2	
	Critical Care Medicine (CCM)	1	
	Endocrinology	2	
	Gastroenterology (GI)	1	
	Hematology/Oncology (H/O)	2	
	Neonatology	1	
	Nephrology	2	
	Neurology	1	
	Rheumatology	1	
Years in practice	Less than 5 years	3 of 14 (21.4%)	
	5 to 10 years	5 (35.7%)	
	10 to 15 years	2 (14.3%)	
	more than 15 years	4 (28.6%)	
Years in PD/APD role	Less than 5 years	9 of 14 (64.3%)	
	5 to 10 years	3 (21.4%)	
	10 to 15 years	2 (14.3%)	
	more than 15 years	0 (0%)	
Currently use POCUS in clinical practice		2 of 14 (14.3%)	Cardiology, Rheumatology
Modality used in current practice	Thoracic	1 of 14 (7.1%)	Cardiology
	Musculoskeletal	2 (14.3%)	Rheumatology
	All others	0	
POCUS modalities beneficial for present/future practice	All modalities	0 of 14 (0%)	
Anticipating importance of POCUS in future practice	Very Important	0 of 14 (0%)	
	Important	4 (28.6%)	Cardiology, Endocrinology, Nephrology, Rheumatology
	Neutral	5 (35.7%)	A/I, Cardiology, CCM, H/O, Neonatology
	Not Important	3 (21.4%)	Endocrinology, Nephrology, Neurology
	Not Important at all	2 (14.3%)	GI, H/O
Currently have a POCUS training curriculum		1 of 14 (7.1%)	CCM
Planning on creating a POCUS training curriculum		0 of 14 (0%)	
Interest in having trainees participate in POCUS curriculum *Note: Denominator excludes CCM, which already had a curriculum.		4 of 13 (30.8%)	Cardiology, Nephrology, Endocrinology, Neonatology
POCUS quality assurance program in place		0 of 14 (0%)	

Table 2. Responses from subspecialty fellows to POCUS survey. (Continues on next page)

Question	Selection	Response No. (%)	Subspecialty
Number of respondents		30 of 95 (31.6%)	
Programs represented	Cardiology	2	
	Critical Care Medicine (CCM)	5	
	Emergency Medicine (EM)	7	
	Endocrinology	4	
	Gastroenterology (GI)	2	
	Hematology/Oncology (H/O)	3	
	Hospitalist Medicine (HM)	1	
	Neonatology	2	
	Nephrology	1	
	Unreported	3	
Post-graduate year	4	7 of 30 (23.3%)	
	5	13 (43.3%)	
	6	9 (30.0%)	
	7	1 (3.3%)	
Currently use POCUS in clinical practice		13 of 30 (40.6%)	Cardiology, CCM, EM, Unreported
Modality used in current practice	Aorta	2 of 30 (6.7%)	Cardiology, EM
	Biliary	1 (3.3%)	EM
	eFAST	7 (23.3%)	EM
	Focused Cardiac	5 (16.7%)	Cardiology, CCM, EM
	Musculoskeletal	5 (16.7%)	EM, Unreported
	Obstetric	2 (6.7%)	EM
	Ocular	3 (10.0%)	EM
	Renal/Bladder	5 (16.7%)	Cardiology, CCM, EM
	Soft tissue	9 (30.0%)	Cardiology, CCM, EM
	Thoracic	3 (10.0%)	Cardiology, CCM, EM
	Vascular/DVT	3 (10.0%)	CCM, EM
	Other Modalities	0	
	Do not perform POCUS	17 (56.7%)	
POCUS modalities fellows want to learn  *Note: Denominator is number of fellows that don't already know the modality*	Abdomen	11 of 30 (36.7%)	CCM, EM, GI, HM, Unreported
	Airway	8 of 30 (26.7%)	Cardiology, CCM, EM, Neonatology, Unreported
	Aorta	3 of 28 (10.7%)	CCM, EM
	Biliary	2 of 29 (6.9%)	EM
	eFAST	6 of 23 (26.1%)	Cardiology, CCM, EM
	Focused Cardiac	9 of 25 (36.0%)	CCM, EM, Neonatology, Unreported
	Male Genitourinary	3 of 30 (10.0%)	EM, Endocrinology

Table 2 (con't). Responses from subspecialty fellows to POCUS survey.

Question	Selection	Response No. (%)	Subspecialty
POCUS modalities fellows want to learn  *Note: Denominator is number of fellows that don't already know the modality*	Musculoskeletal	4 of 25 (16.0%)	EM, H/O
	Obstetric	3 of 28 (10.7%)	EM, Endocrinology
	Ocular	5 of 27 (18.5%)	EM, Unreported
	Renal/Bladder	5 of 25 (20.0%)	CCM, EM, Nephrology
	Soft tissue	4 of 21 (19.0%)	H/O, HM, Unreported
	Thoracic	6 of 27 (22.2%)	CCM, EM, Neonatology
	Thyroid	4 of 30 (13.3%)	Endocrinology
	Vascular/DVT	8 of 27 (29.6%)	CCM, EM, H/O, Neonatology, Unreported
Anticipating importance of POCUS in future practice	Very Important	8 of 30 (26.7%)	CCM, EM, Unreported
	Important	8 (26.7%)	Cardiology, CCM, EM, Endocrinology, HM, Unreported
	Neutral	7 (23.3%)	Cardiology, CCM, Endocrinology, GI, H/O, Neonatology, Unreported
	Not Important	4 (17.4%)	Endocrinology, GI, Neonatology, Nephrology
	Not Important at all	3 (10.0%)	Endocrinology, GI, H/O
Programs with a POCUS training curriculum	Yes	4 of 30 (13.3%)	Cardiology, CCM, EM, Unreported
Interest in participating in POCUS Curriculum  *Note: Denominator is number of fellows from programs that don't already have a program*	Yes	7 of 16 (43.8%)	Endocrinology, GI, Neonatology, Unreported

disconnect in the perceived future importance and current desire to learn POCUS between subspecialty PDs/APDs and their fellows. It is notable that there was significant overlap in the specialties reported for each cohort.

Among residents, there was little current practice, and it is unclear whether the current use is taking place under the guidance of trained practitioners such as in the Emergency Department or Intensive Care Unit. While approximately half of residents that responded indicated that POCUS is important to their future practice, almost all of them expressed desire to learn POCUS, with the most desired modalities being abdomen, soft tissue, and eFAST.

The data from our institution indicate that POCUS training for general pediatric and pediatric subspecialty trainees is believed to be important to future practice, and residency/fellowship programs should strongly consider integrating it into their training. First, aspects of clinical ultrasound are being incorporated into most subspecialty content specifications and require competency in POCUS

in others. Second, if adult medical practice is a roadmap for the eventual direction of pediatric care, it is likely that POCUS will be further incorporated into the standard evaluation of pediatric patients. By having pediatric practitioners proactively adopt POCUS training, our pediatric patients would benefit from the same standard of care that adult patients receive. Third, with regards to future practice, CPT codes have already been established for reimbursement, making POCUS not only useful for patient care, but financially viable [28]. Lastly, a number of trainees reported already using POCUS without formal training, which makes institutions and providers vulnerable to potential medicolegal litigation should these scans be interpreted incorrectly and applied to patient care.

A major limitation of this study is the response rate to the survey, specifically from the trainees, totaling about 1/3 of possible respondents. Another limitation is that this was performed at a single institution and may not reflect attitudes nationally across other pediatric centers. Also,



Table 3. Responses from residents to POCUS survey.

Question	Selection	Response No. (%)
Number of respondents		32 of 82 (39.0%)
Programs represented	General Pediatrics (GP)	17 of 32 (53.1%)
	General Pediatrics/Neurology (GP/N)	3 (9.4%)
	Unreported	12 (37.5%)
Post-graduate year	1	6 of 32 (18.8%)
	2	14 (43.8%)
	3	11 (34.4%)
	4 or higher	1 (3.1%)
Currently use POCUS in clinical practice	GP	5 of 32 (15.6%)
	GP/N	0
	Unreported	4 (12.5%)
Modality used in current practice	Abdominal	2 of 32 (6.3%)
	Biliary	1 (3.1%)
	eFAST	2 (6.3%)
	Musculoskeletal	1 (3.1%)
	Soft tissue	6 (18.8%)
	Other Modalities	0
POCUS modalities beneficial for present/future practice *Note: Denominator unchanged since residents have no formal POCUS training*	Abdomen	19 of 32 (59.4%)
	Airway	11 (34.4%)
	Aorta	4 (12.5%)
	Biliary	6 (18.8%)
	eFAST	16 (50.0%)
	Focused Cardiac	13 (40.6%)
	Male Genitourinary	7 (21.9%)
	Musculoskeletal	14 (43.8%)
	Obstetric	4 (12.5%)
	Ocular	5 (15.6%)
	Renal/Bladder	12 (37.5%)
	Soft tissue	16 (50.0%)
	Thoracic	7 (21.9%)
	Thyroid	3 (9.4%)
	Vascular/DVT	11 (34.4%)
Anticipating importance of POCUS in future practice	Very Important	5 of 32 (15.6%)
	Important	11 (34.4%)
	Neutral	8 (25.0%)
	Not Important	6 (18.8%)
	Not Important at all	2 (6.3%)
Interest in participating in POCUS curriculum	Yes	28 of 32 (87.5%)

results of the study may be skewed by those willing to respond. For example, those who currently have ultrasound curricula and those who desire to learn POCUS may have been more likely to respond to the survey, as evidenced by the fact that PEM and PCCM were the two groups with the highest representation in the fellows' cohort. Finally, perceived ambiguity in the survey and inconsistency in respondents' answers offer some confounding, such as when one cardiology fellow

reported that they had a POCUS curriculum, but the other did not.

### Conclusions

While there is no distinct consensus between trainees and their program leaders regarding the importance of POCUS in pediatric general and subspecialty training, there is significant desire at our institution for education and incorporation of POCUS into training and clinical

care. As POCUS is a relatively new field in pediatrics, it is not entirely surprising that outside of the specialties that have more traditionally used POCUS, namely EM, CCM, and cardiology, there is not significant use of POCUS in clinical decision-making. Additionally, it is not surprising that trainees who are earlier in their career are more likely than their faculty to desire formal training in POCUS be incorporated into their curricula. There is a clear limitation to this study in that the response rate was less than fifty percent, however the study still demonstrates substantial interest at our institution in learning and incorporating a new clinical skill in an area in which current clinical expertise amongst residents, fellows, and subspecialists is clearly lacking. Pediatric training programs should strongly consider integrating POCUS education into their current curricula for residents/fellows given the current trends in training requirements, future viability of POCUS beyond patient care, and possible medicolegal liability of scans being performed by untrained practitioners. While POCUS applications different among the various subspecialties, this study demonstrates that there is a need to incorporate POCUS education into training. Further studies are needed, including a survey of multiple institutions, to evaluate the generalizability of these findings. Other future studies/projects should focus on the creation of a POCUS curriculum with skills that are generalizable across subspecialties, as well as specialty-specific applications.

## Conflict of Interest

The authors have no conflicts of interest to disclose.

## References

1. J.S. Boyd, C.M. LoPresti, M. Core, et al., Current use and training needs of point of care ultrasound in emergency departments: A national survey of VA hospitals, *Am J Emerg Med*. 2019;37:1794-1797. doi: 10.1016/j.ajem.2019.02.043.
2. American College of Emergency Physicians. Ultrasound Guidelines: Emergency, Point-of-Care and Clinical Ultrasound Guidelines in Medicine. *Ann Emerg Med*. 2017;69:e27-e54.
3. Wilson J, Lewiss R, Lum D. Education innovation: A four-week point-of-care ultrasound mini-fellowship for physicians in practice. *Am J Emerg Med*. 2018;36:155-156. doi: 10.1016/j.ajem.2017.07.029.
4. Anstey J, Jensen T, Afshar N. Point-of-care ultrasound needs assessment, curriculum design, and curriculum assessment in a large academic internal medicine residency program. *South Med J*. 2018;111:444-448. doi: 10.14423/SMJ.0000000000000831.
5. Bornemann P. Assessment of a novel point-of-care ultrasound curriculum's effect on competency measures in family medicine graduate medical education. *J Ultrasound Med*. 2017;36:1205-1211. doi: 10.7863/ultra.16.05002.
6. Galen B, Conigliaro R. The Montefiore 10: a pilot curriculum in point-of-care ultrasound for internal medicine residency training. *J Grad Med Educ*. 2018;10:110-111. doi: 10.4300/JGME-D-17-00683.1.
7. Ma I, Arishenkoff S, Wiseman J, et al. Internal Medicine Point-of-Care Ultrasound Curriculum: Consensus Recommendations from the Canadian Internal Medicine Ultrasound (CIMUS) Group. *J Gen Intern Med*. 2017;32:1052-1057. doi: 10.1007/s11606-017-4071-5.
8. Watson et al. Point of care ultrasound training for internal medicine: a Canadian multi-centre learner needs assessment study. *BMC Med Educ* (2018) 18:217. doi: 10.1186/s12909-018-1326-8
9. Pustavoitau A, Blaivas M, Brown S, et al. Recommendations for Achieving and Maintaining Competence and Credentialing in Critical Care Ultrasound with Focused Cardiac Ultrasound and Advanced Critical Care Echocardiography. [http://journals.lww.com/ccmjournal/Documents/Critical\\_Care\\_Ultrasound.pdf](http://journals.lww.com/ccmjournal/Documents/Critical_Care_Ultrasound.pdf). Accessed 6 May 2019.
10. Beal E, Sigmond B, Safe-Silski L, Lahey S, Nguyen V, Bahner D. Point-of-care ultrasound in general surgery residency training. *J Ultrasound Med*. 2017;36:2577-2584. doi: 10.1002/jum.14298.
11. Mok D, Schwarz SKW, Rondi K. Point-of-care ultrasonography in Canadian anesthesiology residency programs: a national survey of program directors. *Can J of Anaesth*. 2017;64:1023-1036. doi:10.1007/s12630-017-0935-8.
12. Niyar V, O'Neill W. Point-of-care ultrasound in the practice of nephrology. *Kidney Int*. 2018;93:1052-1059. doi: 10.1016/j.kint.2017.11.032.
13. Marin JR, Zuckerbraun NS, Kahn JM. Use of Emergency Ultrasound in United States Pediatric Emergency Medicine Fellowship Programs in 2011. *J Ultrasound Med*. <http://onlinelibrary.wiley.com/doi/10.7863/jum.2012.31.9.1357/full>; 2012. Accessed 6 May 2019.
14. Gold DL, Marin JR, Haritos D, et al. Pediatric Emergency Medicine Physicians' Use of Point-of-Care Ultrasound and Barriers to Implementation: A Regional Pilot Study. *AEM Education and Training*. <https://onlinelibrary.wiley.com/doi/abs/10.1002/aet2.10049>; 2017. Accessed 6 May 2019.
15. Marin JR, Lewiss RE, American Academy of Pediatrics, Committee on Pediatric Emergency Medicine, Academy of Emergency Ultrasound, Pediatric Emergency Medicine Committee. Point-of-Care Ultrasonography by Pediatric Emergency Medicine Physicians. *Pediatrics*. <https://pediatrics.aappublications.org/content/135/4/e1113>; 2015. Accessed 6 May 2019.
16. Srinivasan S, Cornell TT. Bedside ultrasound in pediatric critical care: a review. *Pediatric critical care medicine: a journal of the Society of Critical Care Medicine and the World Federation of Pediatric Intensive and Critical Care Societies*. <https://www.ncbi.nlm.nih.gov/pmc/articles/PMC3315182/>; 2011. Accessed 6 May 2019.
17. Hopkins A, Doniger S. Point-of-Care Ultrasound for the Pediatric Hospitalist's Practice. *Hospital Pediatrics*. 2019;9:707-718. DOI: 10.1542/hpeds.2018-0118.
18. American Board of Pediatrics. Content Outlines for Subspecialties. <https://www.abp.org/content/content-outlines-subspecialties>; 2020. Accessed 15 October 2020.
19. American Board of Allergy and Immunology. Item Classification List. <https://www.abai.org/Outline.asp>; 2015. Accessed 29 April 2019.
20. American Board of Anesthesiology. Pediatric Anesthesiology Examination. <http://www.theaba.org/PDFs/Pediatrics-Anesthesiology/PACContentOutline>; 2019. Accessed 29 April 2019.
21. Congenital Cardiac Anesthesia Society. <https://www.ccasociety.org/>; 2020. Accessed 28 April 2020.
22. American Board of Plastic Surgery. Written Examination and Continuous Certification Program Content Outline. <https://www.abplasticsurgery.org/media/13991/ABPS-Content-Outline-final-Approved-5-18-18.pdf>; 2018. Accessed 29 April 2019.
23. American Board of Psychiatry and Neurology. Certification Examination in Child Neurology. [https://www.abpn.com/wp-content/uploads/2017/01/2017\\_Child\\_Neurology\\_CERT\\_Content\\_Specifications.pdf](https://www.abpn.com/wp-content/uploads/2017/01/2017_Child_Neurology_CERT_Content_Specifications.pdf); 2017. Accessed 28 February 2020.
24. American Board of Surgery. Hand Surgery: Content Outline for the Certifying and Recertifying Examinations. <http://www.absurgery.org/xfer/SOTH-CE-RECERT.pdf>; 2009. Accessed 28 February 2020.
25. American Board of Neurological Surgery. American Board of Neurological Surgery Content Categories. <https://abns.org/wp-content/uploads/2018/03/Final-2016-ABNS-Content-Outline.pdf>; 2016. Accessed 28 February 2020.
26. American Board of Orthopedic Surgery. ABOS Part I Certification

Examination Blueprint. [https://www.abos.org/wp-content/uploads/2019/01/abos\\_blueprint\\_part\\_i.pdf](https://www.abos.org/wp-content/uploads/2019/01/abos_blueprint_part_i.pdf); Accessed 28 February 2020.

27. American Board of Physical Medicine and Rehabilitation. Pediatric Rehabilitation Medicine Examination Outline. [https://abpmrprodstorage.file.core.windows.net/pdfs/prm/prm\\_outline.pdf?sv=2018-03-28&sr=s&sig=R5kQdjC5BcPCwkWISWRhJqF%2BGM%2BTCM6UH0fPcuwAAfq%3D&st=2020-02-28T16%3A15%3A02Z&se=2020-02-28T16%3A30%3A02Z&sp=r](https://abpmrprodstorage.file.core.windows.net/pdfs/prm/prm_outline.pdf?sv=2018-03-28&sr=s&sig=R5kQdjC5BcPCwkWISWRhJqF%2BGM%2BTCM6UH0fPcuwAAfq%3D&st=2020-02-28T16%3A15%3A02Z&se=2020-02-28T16%3A30%3A02Z&sp=r); Accessed 28 February 2020.

28. The Society of Point of Care Ultrasound. "SPOCUS Reimbursement Statement." <https://spocus.org/admin-resources/billing-statement/>, Accessed 10/1/2020.

# Tricuspid Regurgitant Jet Velocity Point-of-Care Ultrasound Curriculum Development and Validation

Zachary W. Binder, MD<sup>1,2</sup>; Sharon E. O'Brien, MD<sup>2</sup>; Tehnaz P. Boyle, MD, PhD<sup>2</sup>; Howard J. Cabral, PhD<sup>3</sup>; Joseph R. Pare, MD, MHS<sup>2</sup>

(1) UMass Memorial Medical Center, University of Massachusetts Medical School, Worcester, MA, USA

(2) Boston Medical Center, Boston University School of Medicine, Boston, MA, USA

(3) Boston University School of Public Health, Boston, MA, USA

## Abstract

**Introduction:** The American College of Emergency Physicians (ACEP) recommends that Emergency Medicine physicians with advanced training can evaluate right ventricular (RV) pressures via point-of-care ultrasound (POCUS) by measuring a tricuspid regurgitant jet (TRJ). We were unable to find a published curriculum to deliver education for this at any skill level. Therefore, we developed, delivered, and evaluated a curriculum for the assessment of TRJ for novice physician sonographers. **Methods:** We designed an educational intervention for novice physician sonographers. The curriculum was created using a modified Delphi methodology. All novice sonographers participated in the educational intervention which consisted of a didactic lecture followed by hands-on-deliberate practice on healthy medical student volunteers with expert feedback in a simulated setting. Sonographer's knowledge was assessed at 3 time points: pre-intervention, immediately post-intervention, and 3 months post-intervention (retention assessment) by multiple choice exam. **Results:** Nine novice physician sonographers participated in the intervention. Mean exam performance increased from 55.6% [standard deviation (SD) 11.3%] on the pre-intervention exam to 94.4% (SD 7.3%) on the post-intervention exam and 92.9% (SD 12.5%) on the retention exam. The mean improvement between the pre- and post- exam was +38.9% (95% CI 31.8 - 46.0), and between the pre-exam and retention exam +37.1% (95% CI 22.3 - 52.0). **Conclusion:** Sonographer knowledge of TRJ assessment improved following a brief educational intervention as measured by exam performance. Given the expanding role of POCUS it is increasingly important to provide effective resources for teaching these skills. This work establishes the basis for further study and implementation of our TRJ curriculum.

## Background

Point-of-care ultrasound (POCUS) has emerged as an integral aspect of emergency care and therefore recognized by the Accreditation Council for Graduate Medical Education (ACGME) and American College of Emergency Physicians (ACEP) as a core educational requirement [1,2]. ACEP's policy statement "The Core Content of Clinical Ultrasonography Fellowship Training" states "for situations where there is a concern for increased right ventricular (RV) pressure (i.e. acute pulmonary embolism), Continuous Wave Doppler may be used to estimate RV systolic pressure...by measuring the peak velocity of the tricuspid regurgitant jet (TRJ)" [3]. Tricuspid regurgitant jet velocity can serve as an estimate for RV systolic pressure by using the simplified Bernoulli equation:  $RV \text{ systolic pressure} = 4V^2 + \text{estimated right atrial pressure}$ , where V is the peak TRJ velocity [4]. POCUS serves as a safe and useful diagnostic test to estimate RV systolic pressure which can obviate the need for invasive cardiac procedures.

Although completing a fellowship is one way to gain this

knowledge, it is likely that general Emergency Medicine physicians might also have interest in developing this competency. In addition to these policy statements, there has been interest in emergency physicians' ability to assess for pulmonary hypertension in the Emergency Department (ED) setting. A published review on the evaluation and management of pulmonary hypertension in the ED recommends imaging should include a "chest radiograph and bedside echocardiography" [5]. A case series emphasizes the importance of cardiac POCUS with 8 pediatric patients who received an initial diagnosis of pulmonary hypertension by ED evaluation [6].

Despite the ACEP policy that Emergency Medicine physician's with advanced ultrasound training should consider evaluation of RV pressures by POCUS, and research suggesting the importance of emergency physician's (EP) ability to perform this assessment, we were unable to find a published curriculum to deliver education for this skill at any learner level. Studies have shown that EP sonographers can learn to accurately perform various aspects of a point-of-care



echocardiogram through didactic instruction and practical training [7-12].

### Objectives

We created a curriculum for evaluation of RV pressure by POCUS assessment of tricuspid regurgitant jet velocity (TRJV) that was delivered to a group of novice physician sonographers. The educational intervention was assessed by comparing sonographer scores on a pre-intervention exam, post-intervention exam, and a retention exam at 3 months.

### Methods

We assessed an educational intervention as part of a larger prospective cross-sectional study. The prospective study tested the feasibility of novice physician sonographers to perform echocardiograms of adequate quality to exclude TRJV pathology in Emergency Department patients [13]. The educational intervention was performed in an urban tertiary care level 1 trauma center with an accredited Emergency Medicine residency and Pediatric Emergency Medicine (PEM) fellowship. The Boston University Medical Campus and Boston Medical Center Institutional Review Board approved this work. Study participants provided informed verbal consent.

### Novice Physician Sonographer Population

We designed the educational intervention to be delivered to novice physician sonographers. Based on the ACEP

policy statement we included novice physician sonographers as having performed fewer than 50 echocardiograms [2]. All participants had completed an introductory ultrasound orientation which included basic cardiac ultrasound. Emergency Medicine Interns, Pediatric Emergency Medicine Fellows, and Pediatric Emergency Medicine Attendings were recruited by the principle investigator (PI) as unpaid volunteers. Prospective participants were first contacted by email, followed by in-person enrollment if interested.

### Curriculum Development

The intervention's PI and primary cardiologist created a curriculum as described. A focused literature review led to the generation of a preliminary curriculum [14-16]. The proposed curriculum contained four elements: (1) obtaining an apical 4-chamber view, (2) positioning the color box, (3) optimizing the TRJV color signal, and (4) interrogating with continuous-wave Doppler (Video S1). Each element was subdivided into several critical action steps. The curriculum was then revised and validated using modified Delphi methodology [17,18]. The curriculum was distributed to 3 cardiologists who were otherwise unaffiliated with the intervention. The panel of cardiologists participated in multiple rounds of review and revision. We determined that consensus had been reached when 100% of experts agreed on the main curricular elements and when a majority agreed on each critical action step. The final curriculum contained the 4 main elements and 14 critical action steps (Table 1). The

Table 1. Tricuspid Regurgitant Jet Velocity Curriculum

Curricular Element	Critical Action Step
Apical 4-Chamber View	Image orientation with cardiac apex at the top of screen and left ventricle to the right of screen
	Outline of all four chambers simultaneously visualized
	Image aligned with ultrasound beam parallel to intraventricular septum and perpendicular to Tricuspid Valve
	Image saved of apical 4-chamber view
Color Box Positioning	Color box extending from the back wall of right atrium past the tricuspid valve leaflet tips
	Color box width minimized to just include tricuspid valve orifice
TRJV Color Signal Optimization	Clip saved showing a dynamic sweep through the Tricuspid Valve (anterior → posterior) or (posterior → anterior)
	Select probe position that generates maximal regurgitant color signal
Continuous Wave Doppler	Doppler cursor placed in the middle of tricuspid regurgitant color jet
	Doppler cursor aligned parallel to color jet flow
	Doppler gain adjusted to maximize waveform
	Baseline adjusted to maximize display of wave form
	Image includes three full cardiac cycles
	Image saved with continuous-wave Doppler applied

TRJV = Tricuspid Regurgitant Jet Velocity.

Reproduced with permission from: Binder ZW, O'Brien SE, Boyle TP, et al. "Novice Physician Ultrasound Evaluation of Pediatric Tricuspid Regurgitant Jet Velocity". *Western Journal of Emergency Medicine*. 2020; 21(4): 1029-1035

curriculum served as the central document from which all other intervention documents were generated (exams, didactic lecture, grading rubric).

**Assessment**

Exam questions were developed to provide an objective assessment of the educational intervention. Questions were multiple-choice and correlated to the TRJ curriculum. The questions were developed by the intervention’s PI before undergoing multiple rounds of revision and final approval by a group of content experts in the fields of cardiology and POCUS. This group of experts was distinct from the panel of cardiologists who validated the TRJ curriculum. A total of 20 exam questions were created. Exams were administered at three time points: prior to the educational intervention (pre-intervention assessment), immediately after the educational course (post-intervention assessment), and 3 months after the educational course (retention assessment) (Table 2). Each of the 3 exams contained 10 questions. (Document S1, S2, S3). The pre-intervention exam and post-intervention exam were unique, whereas the retention exam was a random selection of 10 questions from the question bank.

**Curriculum Delivery**

The educational intervention consisted of a 3-hour course that included a didactic lecture (30 minutes) and hands-on workshop (150 minutes) (Table 2). The didactic lecture was derived from the TRJV curriculum and taught sonographers the steps required to obtain TRJV images through still image and video clip modalities. The lecture was prepared and delivered by the intervention’s PI and primary cardiologist. The didactic lecture was modified for the purposes of publication and is included in the supplemental materials (Document S4), along with a video clip of a complete TRJ ultrasound being performed (Video S1).

A hands-on workshop immediately following the didactic lecture consisted of deliberate practice with direct expert feedback. The novice physician sonographers were divided into two groups of four or five participants led by an expert instructor - the primary intervention cardiologist or a professional certified cardiac sonographer. Novice physician sonographers first observed the expert perform image acquisition. This was followed by hands-on practice and the opportunity to observe other novices as they attempted to acquire images with expert guidance. Each sonographer practiced image acquisition on four human models and received guided feedback from each of the instructors. Each sonographer completed a minimum of 5 practice scans during the workshop followed by one graded scan. The instructors used a developed image grading rubric to grade scans

*Table 2. Educational Intervention Format*

Educational Component	Duration	Content
Pre-Exam	15 minutes	10 multiple choice questions
Didactic Lecture	30 minutes	Still image and video clip based
Hands-On Workshop	150 minutes	Deliberate practice with expert feedback
Post-Exam	15 minutes	10 multiple choice questions
Scanning Window	3 months	Prospective intervention study [13]
Retention Exam	15 minutes	10 multiple choice questions

(Document S5) [13]. Scans received a maximum score of 4 with each element receiving a complete (1), incomplete (0) or not performed (0). A passing grade required a score of 4 out of 4. Novice physician sonographers who were unable to pass on their initial attempt received additional focused feedback and time to practice until they were able to perform a passing scan. The graded scans established the novice’s ability to obtain TRJ images.

**Ultrasound Models**

All ultrasound models used during the educational intervention were healthy medical student volunteers. All models were initially recruited through an advertisement in the medical school e-newsletter. Models were paid a financial stipend. There was a certified cardiologist on hand at all times during the educational intervention who was prepared to privately disclose any incidental findings to the volunteer models who would then be encouraged to follow-up with their primary care physician. No incidental findings were discovered during the hands-on session.

**Statistical Analysis**

Descriptive statistics and paired t-test were performed to analyze the data. All statistical analyses were performed using STATA v 13.1 (College Station, TX).

**Results**

Nine novice physician sonographers participated in the educational intervention (3 Emergency Medicine Interns, 2 Pediatric Emergency Medicine Fellows, and 4 Pediatric Emergency Medicine Attendings). Five (55.5%) of the

Table 3. Sonographer Exam Results.

2.A Exam Scores (n=9)			
	Mean	SD	Range
Pre-Exam	55.6%	+/- 11.3%	40-80%
Post-Exam	94.4%	+/- 7.3%	80-100%
Retention Exam *	92.9%	+/- 12.5%	70-100%
2.B Score Change			
	% Change [95% CI]	SD	P value
Pre-Exam→Post-Exam	+38.9 [+31.8 - +46.0]	+/- 9.3	0.0001
Pre-Exam→Retention Exam *	+37.1 [+22.3 - +52.0]	+/- 16.0	0.0001

SD = Standard Deviation; CI = Confidence Interval

\* n = 7

participants were female. Two of the sonographers (one Emergency Medicine Intern, and one Pediatric Emergency Medicine Attending) dropped out after the educational intervention due to time constraints. They did not complete the retention exam.

At the conclusion of the hands-on session, all participating sonographers successfully passed the test scan with a score of 4 out of 4 on their first attempt, within the allotted 3 hours. Table 3 shows sonographer exam results.

## Discussion

A primary goal of this publication is to make available our educational intervention with exams to further the resources available for point of care ultrasound learners. The accompanied knowledge evaluation shows retention of this curriculum was strong even at 3 months.

The intervention found a statistically significant improvement in sonographer exam performance following the educational intervention. This improvement was maintained after an interval period of 3 months. These results are consistent with prior studies that have shown emergency medicine physicians can accurately assess and measure components of a POCUS echocardiogram after educational interventions that include didactic instruction and hands-on training [7-12]. To our knowledge this intervention represents the first time that an educational intervention aimed at teaching TRJV has been tested. We believe this manuscript provides preliminary evidence that this educational intervention improves key knowledge regarding the principles and skills required for the evaluation of TRJV.

Obtaining expertise for a given POCUS application has multiple stages. One must first obtain the applicable

knowledge, then learn to physically perform the scan, and finally learn to interpret their images in order to integrate clinically. Sonographers performed well on the post intervention assessment which tested accrued knowledge (initial stage).

A previously published prospective research study by Binder et al. tested sonographer's ability to physically perform TRJV scans (second stage) [13]. During that study novice physician sonographers were graded by the study's primary cardiologist using the same grading rubric as this educational intervention (**Document S5**). In that study novice sonographers obtained a satisfactory apical 4-chamber view in 85% (95% CI 77.1-92.9), positioned the color box accurately 65% (95% CI 54.5-75.5), optimized TRJV color signal 78.7% (95% CI 69.8-87.7), and optimized continuous-wave Doppler in 55% (95% CI 44.1-66.0) of echocardiograms [13]. Future research into the implementation of this curriculum could compare novice performance to the gold standard of sonographer performed comprehensive echocardiogram to provide further validation of skill acquisition.

## Limitations

We focused on one method for assessing for pulmonary hypertension, tricuspid regurgitant jet velocity, in an apical 4-chamber window. The American Society of Echocardiography Guidelines suggests interrogating the tricuspid regurgitant jet velocity in multiple windows which was not included as part of this educational intervention.<sup>4</sup> This intervention was not intended to teach all the components of a comprehensive cardiac point-of-care ultrasound. It should also be noted that the use of tricuspid regurgitant jet velocity as an estimate for RV systolic pressure requires estimation and addition of the right atrial pressure. Complete evaluation should also

assess for obstruction at the pulmonic valve and RV outflow tract which was not done during this novice educational intervention.<sup>4</sup>

Additional echocardiographic findings such as “right atrial enlargement, RV dilatation, increased RV free wall thickness, end-systolic flattening of the intraventricular septum, and interventricular interdependence visualized as a ‘D’- shaped left ventricle in diastole” can be used to aid the diagnosis of pulmonary hypertension [5]. These additional techniques were not taught nor tested as part of this curriculum. Additionally, the curriculum did not incorporate pulsed-wave Doppler prior to continuous-wave Doppler analysis. The risk in excluding pulsed-wave Doppler is overestimating the TRJV through contamination of signal from extremely rare intra-cardiac shunting lesions. This is an accepted practice in echocardiography and has been used in prior studies on the topic [19].

This evaluation of the educational intervention was limited to 7 participants. We hope to replicate our results on a larger sample of participants in the future.

## Conclusions

Based on national recommendations that emergency medicine physicians with advanced ultrasound training are expected to learn, perform and interpret a TRJV as part of POCUS echocardiography we chose to develop a curriculum to teach this skill to novices. The curriculum was able to greatly improve knowledge as tested by multiple choice exam, however capability of hands-on skills varied. This work establishes the basis for further study and implementation of the TRJV curriculum.

## Acknowledgements

Table 1 is reproduced with permission from: Binder ZW, O'Brien SE, Boyle TP, et al. “Novice Physician Ultrasound Evaluation of Pediatric Tricuspid Regurgitant Jet Velocity”. *Western Journal of Emergency Medicine*. 2020; 21(4): 1029-1035

## Statement of Ethics Approval/Consent

This study was approved and monitored by the institution's IRB. All participants provided informed consent prior to participation.

## Disclosures

The study authors have no financial or other conflicts of interest in relation to this study.

## References

1. *Emergency Medicine Defined Key Index Procedure Minimums*. Chicago: Accreditation Council for Graduate Medication Education; 2017.
2. Tayal VS, Raio CC. *ACEP Policy Statement - Ultrasound Guidelines:*

*Emergency, Point-of-Care, and Clinical Ultrasound Guidelines in Medicine.*; 2016.

3. Lewiss RE, Tayal VS, Hoffmann B, et al. The Core Content of Clinical Ultrasonography Fellowship Training. *Academic Emergency Medicine*. 2014;21(4):456-461.

4. Rudski LG, Lai WW, Afilalo J, et al. Guidelines for the Echocardiographic Assessment of the Right Heart in Adults: A Report from the American Society of Echocardiography Endorsed by the European Association of Echocardiography, a registered branch of the European Society of Cardiology, and the Canadian Society of Echocardiography. *J Am Soc Echocardiogr*. 2010;23(7):685-713.

5. Simon E, Bridwell RE, Montrieff T, et al. Evaluation and management of pulmonary hypertension in the emergency department setting. *Am J of Emerg Med*. Advance Online Publication.

6. Dessie A, Leung S, Amico BD, et al. Focused cardiac ultrasound to expedite diagnosis of pulmonary hypertension in children in the emergency department. *Am J Emerg Med*. 2020;38(3):629-637.

7. Mandavia DP, Hoffner RJ, Mahaney K, et al. Bedside echocardiography by emergency physicians. *Ann Emerg Med*. 2001;38(4):377-382.

8. Longjohn M, Wan J, Joshi V, et al. Point-of-care echocardiography by pediatric emergency physicians. *Pediatr Emerg Care*. 2011;27(8):693-696.

9. Daley J, Grotberg J, Pare J, et al. Emergency physician performed tricuspid annular plane systolic excursion in the evaluation of suspected pulmonary embolism. *Am J Emerg Med*. 2017;35:106-111.

10. Hall MK, Coffey EC, Herbst M, et al. The “5Es” of Emergency physician-performed focused cardiac ultrasound: A protocol for rapid identification of effusion, ejection, equality, exit, and entrance. *Acad Emerg Med*. 2015;22(5):583-593.

11. Del Rios M, Colla J, Kotini-Shah P, et al. Emergency physician use of tissue Doppler bedside echocardiography in detecting diastolic dysfunction: an exploratory study. *Crit Ultrasound J*. 2018;10(1).

12. Ehrman RR, Russell FM, Ansari AH, et al. Can emergency physicians diagnose and correctly classify diastolic dysfunction using bedside echocardiography? *Am J Emerg Med*. 2015;33(9):1178-1183.

13. Binder ZW, O'Brien SE, Boyle TP, et al. “Novice Physician Ultrasound Evaluation of Pediatric Tricuspid Regurgitant Jet Velocity”. *Western Journal of Emergency Medicine*. 2020; 21(4): 1029-1035.

14. Solomon SD. *Essential Echocardiography: A Practical Guide with DVD*. Totowa, NJ: Humana Press Inc.; 2007.

15. Snider AR, Serwer GA, Ritter AB. *Echocardiography in Pediatric Heart Disease*. Maryland Heights, MO: Mosby; 1990.

16. 16.2.2.1 Tricuspid regurgitation signal to measure pulmonary pressure. 123sonography website. Available at <https://www.123sonography.com/ebook/how-assess-pulmonary-hypertention>. Accessed July 1, 2019

17. Clayton M. Delphi: a technique to harness expert opinion for critical decision-making tasks in education. *Educ Psychol*. 1997;17:373-386.

18. Werner HC, Vieira RL, Rempell RG, et al. An educational intervention to improve ultrasound competency in ultrasound-guided central venous access. *Pediatr Emerg Care*. 2016;32(1):1-5.

19. Currie PJ, Seward JB, Chan KL, et al. Continuous wave doppler determination of right ventricular pressure: A simultaneous Doppler-catheterization study in 127 patients. *J Am Coll Cardiol*. 1985;6(4):750-756.



# Comparison of Clerkship Directors' Expectations of Physical Examination Skills with Point-of-care Ultrasound Skills Using the RIME Framework

Valérie Desjardins, BSc<sup>1</sup>; Paul Pageau, MD<sup>2</sup>; Barbara Power, MD<sup>3</sup>; Isabelle Burnier, MD, M.Ed<sup>1</sup>; Carolina Souza, MD, PhD<sup>4</sup>; Warren J. Cheung, MD, MMed<sup>5</sup>; Michael Y. Woo, MD<sup>5</sup>

(1) University of Ottawa

(2) Department of Emergency Medicine, University of Ottawa and The Ottawa Hospital

(3) Department of Medicine, University of Ottawa and The Ottawa Hospital

(4) Department of Radiology, University of Ottawa and The Ottawa Hospital

(5) Department of Emergency Medicine, University of Ottawa and Ottawa Hospital Research Institute

## Abstract

**Background:** The expectations of point-of-care ultrasound (PoCUS) in undergraduate clerkship at the University of Ottawa has not been described. We compared clerkship directors' expectations of physical examination skills with PoCUS skills, before and after completing the clerkship rotation. **Methods:** A pilot-tested, expert developed, bilingual on-line survey consisting of 15 questions was sent to all clerkship directors (23) in December 2019. The survey included questions regarding the expectations of medical students with respect to physical examination and PoCUS using the RIME Framework: none, reporter, interpreter, manager, educator. **Results:** The response rate was 60.9% (14/23). With regards to physical exam skills, 82.8% of directors had no expectations or expected students to be reporters when starting clerkship. At graduation, 77.5% of directors expected students to be interpreters, managers, or educators. For PoCUS, 100.0% of directors had no expectations or expected students to be reporters when starting clerkship. At clerkship completion, 33.0% of directors felt that students should be interpreters or managers for PoCUS skills. **Conclusions:** Clerkship directors have low expectations of PoCUS skills for entering and graduating clerks when compared with their physical examination skills despite formal pre-clerkship PoCUS objectives. Enhanced communication and targeted education of directors could improve the PoCUS curriculum.

## Background

Point-of-care ultrasound (PoCUS), a diagnostic or procedural ultrasound performed by a physician at the bedside, is changing the way many clinicians practice medicine. PoCUS is described as being a useful adjunct to the physical examination, such as the stethoscope or reflex hammer, that can improve clinical judgement and patient satisfaction [1-5]. In 2016, a survey indicated that approximately half of Canadian medical schools teach PoCUS to their medical students [6]. The University of Ottawa has physical examination skills objectives throughout the four years of medical school, and more recently, PoCUS skills objectives for their pre-clerkship students (<https://med.uottawa.ca/undergraduate/students/student-zone/pre-clerkship>).

The current expectations regarding PoCUS skills in undergraduate clerkship at the University of Ottawa medical school has not been described. This survey compares the expectations of PoCUS examination to the physical exam. PoCUS skills were taught in conjunction

with Physicians Skills Development (PSD). PoCUS skills have also been described as an adjunct to the physical exam. The objective of the survey is to compare the Clerkship Directors' expectations of overall student performance before and after completing clerkship as a whole, with respect to physical examination skills and PoCUS skills using the RIME framework [7].

The framework used is based on the RIME mnemonic: Reporter, Interpreter, Manager, Educator. Anchor definitions were applied in the following manner: a *reporter* can obtain and communicate the examination (eg. inspect, palpate, percuss, auscultate or identify PoCUS abnormalities), an *interpreter* can analyze and interpret the examination (eg. find possible cause of abnormality), a *manager* can integrate the examination and propose treatments (eg. determine management plan), and an *educator* can teach other students how to perform and integrate the findings of an examination (eg. teach pre-clerkship students to be a reporter, interpreter, and manager of a particular exam).

## Methods

A bilingual (English/French) online survey was administered in December 2019. The survey was developed by a PoCUS expert from Emergency Medicine, a radiologist, the anglophone and francophone directors of Clinical Skills at the University of Ottawa medical school, and a second-year medical student. The survey was pilot tested with three physicians (Family Medicine and Emergency Medicine) and six medical students. The Ottawa Health Science Network Research Ethics Board (OHSN-REB) waived its review and the project was deemed REB exempt.

The final survey was composed of three sections with a total of 15 questions: general demographics, expectations for the physical examination, expectation for the PoCUS examination. Five types of examinations were surveyed for both the physical examination and PoCUS: cardiovascular, respiratory, abdominal, musculoskeletal, and thyroid (online supplementary Appendix A). Respondents were asked to categorize each physical examination skill or PoCUS item based on anchors from the RIME Framework that described their expectation of the specific examination for the medical student, pre and post clerkship [7]. Differences between the five types of examinations were assessed by an unpaired t-test. The five types of examinations were then grouped together to compare the expectations for the physical examination and the POCUS examinations directly.

The survey was distributed by SurveyMonkey (San Mateo, USA) on December 3, 2019 to a total of 23 clerkship rotation directors. Follow-up reminders were sent to non-responders after one week and two weeks.

A single data abstractor collected and analyzed the data using GraphPad Prism (San Diego, USA). Descriptive statistics were performed. Responses were kept anonymous, and all data was reported in aggregate.

## Results

14 of the 23 undergraduate clerkship directors at the University of Ottawa medical school responded to the survey, for a response rate of 60.9%. The demographic information and PoCUS use of respondents are summarized in Table 1. The majority of clerkship directors (57.1%) have been practicing medicine for over 10 years and come from various specialties. Half of the respondents use PoCUS in their medical practice. Of the seven respondents who do not currently use POCUS, three would practice if given the opportunity to learn (21.4%), two would consider it (14.3%), and two would not practice PoCUS even if given the opportunity (14.3%). There was no statistical difference between the five types of examinations.

Table 1. Demographics of clerkship rotation directors.

Years as practicing physician		N (%)
<5 years		3 (21.4)
5-10 years		3 (21.4)
>10 years		8 (57.1)
Physician specialties		
Family Medicine		2 (14.3)
Obstetrics and Gynecology		2 (14.3)
Anesthesiology		2 (14.3)
Psychiatry		1 (7.1)
General Internal Medicine		2 (14.3)
Geriatrics		1 (7.1)
Endocrinology		1 (7.1)
Emergency Medicine		1 (7.1)
Pediatrics		1 (7.1)
Otolaryngology		1 (7.1)
PoCUS use in medical practice		
Yes		7 (50.0)
No		7 (50.0)

N=14; PoCUS – point-of-care ultrasound

### Expectations upon entering clerkship

Regarding the physical examination, most responders (82.8 %) had no expectations (30.8%) or expected students to be reporters (52.0%). Regarding the PoCUS examination for students entering clerkship, all respondents had no expectations (66.8%) or expected students to be reporters (33.2%).

### Expectations upon completing clerkship

Regarding the physical examination, 77.5% of the clerkship directors felt the student should be interpreters (38.3%), managers (27.6%), or educators (11.6%) of specific physical examinations, while the remaining respondents (22.5%) had no expectations (8.7%) or expected the graduating students to be reporters (13.8%). For students completing clerkship, 33.0% of respondents believe students should be interpreters (18.4%) or managers (14.8%).

### Expectations of clerkship directors who use PoCUS

Clerkship directors who use PoCUS in their practice had higher ultrasound expectations for students completing clerkship than those who do not use PoCUS. Differences between clerkship directors who use PoCUS and those who do not were assessed by an unpaired t-test followed by a Holm-Sidak post-hoc test, with the data for the five types of examinations grouped to compare the RIME framework. 40.0% of clerkship directors who use PoCUS in their practice expect the graduating students to be

*Table 2. Expectations of clerkship directors entering and leaving clerkship for physical exam and PoCUS using the RIME Framework.*

	Physical Examination Skills Expectations		PoCUS Skills Expectations	
	Entering Clerkship N (%)	Leaving Clerkship N (%)	Entering Clerkship N (%)	Leaving Clerkship N (%)
None	67 (30.8)	23 (8.7)	141 (66.8)	110 (51.8)
Reporter	125 (52.0)	29 (13.8)	69 (33.2)	31 (15.0)
Interpreter	39 (17.2)	88 (38.3)	0	36 (18.4)
Manager	0	65 (27.6)	0	33 (14.8)
Educator	0	26 (11.6)	0	0

*N represents the amount of times the clerkship directors have selected the RIME Framework description for the five types of examinations surveyed (cardiovascular, respiratory, abdominal, musculoskeletal, and thyroid).*

interpreters or managers, compared to 26.4% of non-PoCUS users ( $p < 0.05$ ).

Clerkship director's expectation of students starting and completing clerkship for the physical exam and PoCUS are illustrated in Table 2.

## Discussion

The physical examination skills objectives are clearly stated in the undergraduate medical education curriculum at the University of Ottawa, for both the pre-clerkship and clerkship programs. There are clear and available PoCUS objectives for pre-clerkship. However, clerkship PoCUS objectives are not easily available for all members of the Undergraduate Medical Education Faculty, since the objectives on the clerkship website are split into the different rotations and none of them explicitly mention PoCUS. Using the RIME framework, the results of this study indicate that the expectations for the physical examination increase for students completing clerkship. It is surprising that only 17.2% of clerkship directors felt that a student entering clerkship should be able to interpret a physical examination, despite objectives in pre-clerkship describing being able to analyze and interpret the abnormalities of a physical examination. Similarly, Wenrich et al. found that preclinical faculty and medical students had much higher expectations than clerkship faculty for most clinical skills [8].

PoCUS is described as being an useful adjunct to the physical examination that improves clinical judgement and patient satisfaction [1-5]. Formal pre-clerkship PoCUS curriculum objectives were introduced in 2018 at the University of Ottawa. Nonetheless, clerkship directors have little to no expectations with respect PoCUS skills for the student entering clerkship (66.8% had no expectations and 33.2% expected reporters). There is a marginal increase in these expectations for the graduating clerk, with 33.0% of directors expecting interpreters or managers of PoCUS skills. Overall, this

study highlights the need to strengthen communication of expectations between the pre-clerkship and clerkship faculty and to promote familiarity with the pre-clerkship PoCUS skills objectives, as clerkship directors are perhaps not aware of any PoCUS teaching in pre-clerkship or that objectives were added to the curriculum. It is important to establish formal clerkship objectives to provide continued PoCUS learning for medical students at the University of Ottawa. This would greatly benefit medical students by providing consistent communication of what skills and abilities are expected of them, especially when entering clerkship [8-10]. It is also possible that clerkship directors feel that PoCUS is not a useful clinical skill for the graduating medical student to possess, despite evidence that ultrasonography is a valuable teaching tool that enhances medical education [9]. Since the clerkship directors who do not use PoCUS in their medical practice tend to have lower expectations of their clerks in regard to PoCUS skills, targeted education of these directors could be an important step in the implementation of PoCUS objectives in clerkship.

As with all survey designs, one limitation of this study is the possibility of sample bias. Program directors using PoCUS in their medical practice might have been more likely to respond to the survey than those who do not. Additionally, one clerkship director misunderstood the purpose of the study as described in the survey, and indicated their expectations in relation to the completion of their specific rotation, rather than completion of clerkship as a whole. Finally, it's possible that respondents were not familiar with the RIME framework used to define level of performance of their students. However, we attempted to mitigate this by providing descriptive anchors for each level of the framework.

## Conclusion

Clerkship rotation directors have little expectations of entering and graduating clerks with regards to their PoCUS skills when compared with their physical

examination skills. These differing expectations exist despite formal PoCUS objective in the pre-clerkship curriculum. Improved communication between pre-clerkship and clerkship faculty as well as targeted education of clerkship directors could be an important step to improve the implementation of a PoCUS curriculum in clerkship. Further study is required to uncover the cause of this discrepancy between physical examination skills and POCUS skills expectations.

### Acknowledgements:

We would like to thank the POCUS Interest Group, medical students, and Clerkship Directors for participating in the program evaluation and the Undergraduate Medical Education at the University of Ottawa for their support.

There was no funding for this program evaluation.

### Conflicts of Interest Notification

Valérie D. Desjardins, Dr. Paul Pageau, Dr Barbara Power, Dr Isabelle Burnier, and Dr. Warren J. Cheung have no conflicts of interest. Dr Carolina Souza - Advisory board: AstraZeneca, Boehringer-Ingelheim. Consultant fees and honorarium: Pfizer, Boehringer-Ingelheim, AstraZeneca, Hoffmann-La Roche. Educational Grant: Boehringer-Ingelheim. Dr Michael Y. Woo, MD – Teaching Chair - POCUS, Undergraduate Medical Education, University of Ottawa.

### References

1. Siepel T, Clifford DS, James PA, Cowan TM. "The ultrasound-assisted physical examination in the periodic health evaluation of the elderly". *J Fam Pract*. 2000;49(7):628-632. PMID 10923573.
2. Rosenthal TC, Siepel T, Zubler J, Horwitz M. "The use of ultrasonography to scan the abdomen of patients presenting for routine physical examinations". *J Fam Pract*. 1994;38(4):380-385. PMID 8163963.
3. Howard ZD, Noble VE, Marill KA, et al. "Bedside ultrasound maximizes patient satisfaction". *J Emerg Med*. 2014;46(1):46-53. <https://doi.org/10.1016/j.jemermed.2013.05.044>
4. Inglis AJ, Nalos M, Sue KH, et al. "Bedside lung ultrasound, mobile radiography and physical examination: a comparative analysis of diagnostic tools in the critically ill". *Crit Care Resusc*. 2016;18(2):124. PMID 27242110.
5. Mantuani D, Frazee BW, Fahimi J, Nagdev A. "Point-of-Care Multi-Organ Ultrasound Improves Diagnostic Accuracy in Adults Presenting to the Emergency Department with Acute Dyspnea". *West J Emerg Med*. 2016;17(1):46-53. <https://doi.org/10.5811/westjem.2015.11.28525>
6. Steinmetz P, Dobrescu O, Oleskevich S, Lewis J. "Bedside ultrasound education in Canadian medical schools: A national survey". *Can Med Educ J*. 2016 Mar 31;7(1):e78-86. PMID 27103956.
7. Pangaro L. "A new vocabulary and other innovations for improving descriptive in-training evaluations". *Acad Med*. 1999;74(11):1203-1207. <https://doi.org/10.1097/00001888-199911000-00012>
8. Wenrich M, Jackson MB, Scherpbier AJ, Wolfhagen IH, Ramsey PG, Goldstein EA. "Ready or not? Expectations of faculty and medical students for clinical skills preparation for clerkships". *Med Educ Online*. 2010 Aug 6;15. <https://doi.org/10.3402/meo.v15i0.5295>
9. Hoppmann RA, Rao VV, Poston MB, et al. "An integrated ultrasound curriculum (iUSC) for medical students: 4-year experience". *Crit Ultrasound J*. 2011 Apr;3(1):1-12. <https://doi.org/10.1007/s13089-011RInt-0052-9>
10. O'Brien B, Cooke M, Irby DM. "Perceptions and attributions of third-year student struggles in clerkships: do students and clerkship directors agree?". *Acad Med*. 2007 Oct;82(10):970-8. <https://doi.org/10.1097/acm.0b013e31814a4fd5>



# The Use of Thoracic Ultrasound to Predict Transudative and Exudative Pleural Effusion

Peter T. Evans MD<sup>1†</sup>; Robert S. Zhang MD<sup>1†</sup>; Yulei Cao MS<sup>2</sup>; Sean Breslin MD<sup>1</sup>; Nova Panebianco MD, MPH<sup>3</sup>; Cameron M. Baston MD, MSCE<sup>1,4</sup>; David M. DiBardino, MD<sup>1,4</sup>

(1) Department of Medicine, University of Pennsylvania, Philadelphia, PA

(2) Drexel University College of Medicine, Philadelphia, PA

(3) Department of Emergency Medicine, University of Pennsylvania, Philadelphia, PA

(4) Section of Interventional Pulmonology and Thoracic Oncology, Division of Pulmonary, Allergy and Critical Care, University of Pennsylvania, Philadelphia, PA

<sup>†</sup> PE and RSZ contributed equally to this work

## Abstract

**Objectives:** Pleural effusion is a common reason for hospital admission with thoracentesis often required to diagnose an underlying cause. This study aimed to determine if the imaging characteristics of TUS effectively differentiates between transudative and exudative pleural fluid. **Methods:** Patients undergoing TUS with pleural fluid analysis were retrospectively identified at a single center between July 2016 and March 2018. TUS images were interpreted and characterized by established criteria. We determined diagnostic performance characteristics of image criteria to distinguish transudative from exudative pleural effusions. **Results:** 166 patients underwent thoracentesis for fluid analysis of which 48% had a known malignancy. 74% of the pleural effusions were characterized as exudative by Light's Criteria. TUS demonstrated anechoic effusions in 118 (71%) of samples. The presences of septations on TUS was highly specific in for exudative effusions (95.2%) with high positive predictive values (89.5%) and likelihood ratio (2.85). No TUS characteristics, even when adjusting for patient characteristics such as heart failure or malignancy, were sensitive for exudative effusions. **Conclusions:** Among our cohort, anechoic images did not allow reliable differentiation between transudative and exudative fluid. Presence of complex septated or complex homogenous appearance was high specific and predictive of exudative fluid.

## Background

Over 1.5 million people develop pleural effusion each year and there is an estimated prevalence of 60% in the intensive care unit (ICU) [1,2]. Thoracic ultrasound (TUS) has been shown to be more sensitive than chest radiography and physical examination for pleural effusion and is routinely used to detect and evaluate pleural effusions [3]. Although the use of TUS to guide thoracentesis has improved procedural safety and should be considered standard of care, there are still risks associated with the procedure [4,5]. The ability to predict the chemical characteristics of a pleural effusion prior to sampling may impact subsequent management and potentially decrease the need for thoracentesis and associated procedural risks. There have been limited data that have examined the diagnostic accuracy of TUS's ability to differentiate a transudative from an exudative effusion. Most prior studies have shown that TUS was reliable in identifying exudative effusions but not transudative effusion; however, outside of a recent evaluation by Shkolnik and Asciak et al, these studies were older with different technology, and often had smaller sample sizes [6–9].

In this study, we examined the diagnostic performance of TUS in predicting transudative and exudative effusions.

## Methods

### *Study Population and Data Collection*

This study was approved by the University of Pennsylvania Institutional Review Board (IRB number 828853). The requirement for written informed consent was waived by the board. We retrospectively identified consecutive patients who were evaluated by the procedure service for consideration for thoracentesis with archived pleural effusion images at a single large academic center between July 2016 and March 2018. At our center thoracenteses performed on the acute care medicine floors are performed by a dedicated procedure service staffed by Nurse Practitioners and Physician Assistants supervised by Pulmonary and Critical Care faculty. The service performs approximately 600 thoracenteses per year.

Patient clinical, demographic and pleural fluid analysis data were abstracted via chart review by physicians. TUS was performed with a Sonosite Xpore machine using a

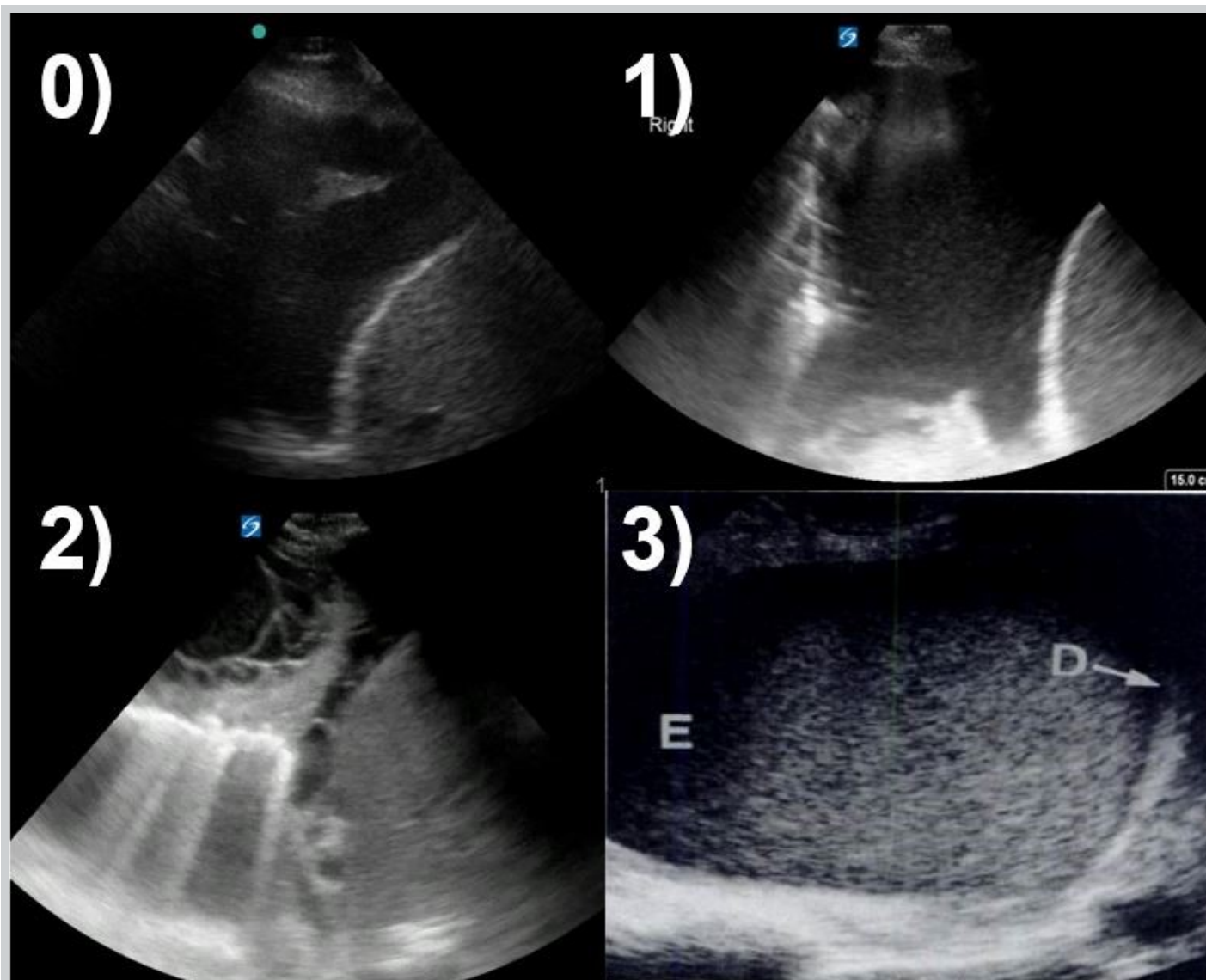


Figure 1. Sample pleural fluid images. 0, anechoic – no echoes present between the pleura and diaphragm; 1, complex, non-septated – increased echogenicity of the space between the pleura and diaphragm, without clear hyperechoic linear findings to suggest septation; 2, complex, septated – echogenic linear structures present in the space between the pleura and diaphragm; 3, homogeneously echogenic – echogenic material filling the entire space between the pleura and diaphragm.

phased-array sector transducer in the abdominal preset. The other acquisition specifics, including gain, depth, and patient positioning were left to the discretion of the operator. TUS was performed by multiple operators with experience in lung ultrasound. All pleural effusions included a short video clip and/or still images identifying the diaphragm, pleural effusion and lung parenchyma. The TUS images were analyzed retrospectively by board certified pulmonary and critical care physicians (CB and DD) who were blinded to the clinical data (including Light's criteria) and prior image interpretation. Disagreement between two primary reviewers was arbitrated by an ultrasound fellowship trained physician (NP).

The TUS images of the pleural effusions were classified by previously published criteria [6,7]. Anechoic was defined by no echoes present between the visceral pleural and diaphragm. Complex, nonseptated was defined by an increased echogenicity of the space between the visceral pleura and diaphragm, without clear hyperechoic linear findings to suggest septation. Complex, septated was defined as echogenic linear structures presenting in the space between the visceral pleura and diaphragm. Homogeneously echogenic was defined as echogenic material filling the entire space between pleural and diaphragm. Figure 1. demonstrates representative imaging.

The decision to complete a thoracentesis was made by

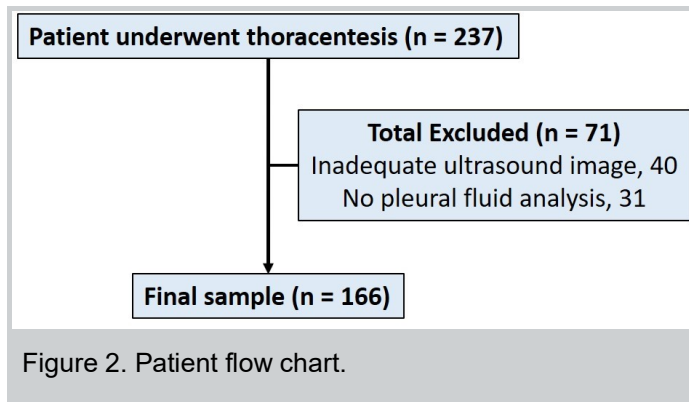


Table 1. Baseline characteristics

	N=166
BMI, kg/m (mean, SD)	29 (18)
Female sex (%)	69 (41.5%)
Malignancy	81 (48%)
Infection	9 (5%)
Hepatohydrothorax	22 (14%)
Heart failure	11 (7%)

the primary team (rather than procedure service performing the imaging and thoracentesis), unless TUS demonstrated lack of adequate volume for safe drainage or other safety concerns. Pleural fluid was sent for analysis and specific tests were ordered by the primary team and typically included: gram stain and culture, pH, lactate dehydrogenase (LDH), cell count and differential, total protein, glucose, and cytology. It was standard practice for the primary team to send serum LDH and total protein at the time of the procedure.

Pleural effusions were classified as exudative or transudative based on the Light's criteria [10]. An exudative effusion was defined as a parapneumonic effusion if there was evidence of an adjacent pneumonia or lung abscess, positive gram stain or culture, or biochemical evidence of inflammation (pH <7.20 or glucose <60). Empyema was identified if the effusion had frank purulent drainage. An exudative effusion was defined as malignant if there was evidence based on cytology, flow cytometry, histology or known cancer without an alternative cause of the effusion.

### Statistical Analysis

Continuous variables are presented as mean  $\pm$  standard deviation (SD) or median with interquartile range (IQR) for skewed data. Categorical data are expressed as frequencies and proportions. Logistic regression was used to determine the relationship between sonographic

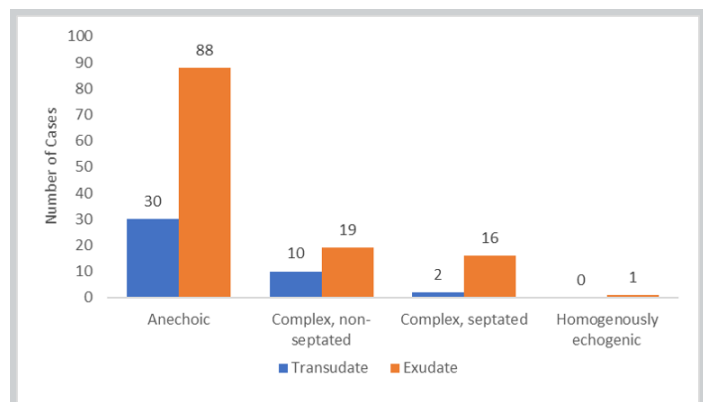


Figure 3. Distribution of effusion studies by thoracic ultrasound image characteristics.

Table 2. Distribution of Pleural Diagnoses by Thoracic Ultrasound.

	Transudate	Exudate	Total
Anechoic	30	88	118
Complex, non-septated	10	19	29
Complex, septated	2	16	18
Homogenously echogenic	0	1	1
Total	42	124	166

findings and final categorization of the effusion based on the Light's criteria. Cohen's kappa coefficient was calculated to determine the inter-observer agreement for the sonographic score. Two by two tables were created to determine the sensitivity, specificity, positive predictive value and negative predictive value. Analyses were performed using Stata version 15 (College Station, TX: StataCorp LLC).

### Results

Our analysis included 166 thoracenteses performed (Figure 2). Patients' mean BMI was 29.4 and 41.5% of patients were female. Patient demographics characteristics are described in Table 1.

Ultrasound images included 118 images that were anechoic, 29 complex and non-septated, 18 complex and septated, and 1 homogenously echogenic. Figure 3 displays the relationship between the TUS findings with a pleural effusion classification of transudative vs exudative. After laboratory analysis, 124 (74%) were exudative by Light's criteria, while 42 (25%) were transudative. The etiologies of effusion included malignancy (48%), infection (5%), hepatohydrothorax (14%), heart failure (7%) and other (26%). The breakdown of ultrasound image characteristic and fluid sampling is outline in Table 2.

*Table 3. Diagnostic Performance of Ultrasound Score to Predict Exudative Effusions.*

	Sensitivity (95% CI)	Specificity (95% CI)	PPV (95% CI)	NPV (95% CI)	Positive LR (95% CI)
Nonzero sonographic score (%)	29 (21-38)	71 (55-84)	74 (60-86)	25 (18-34)	1.0 (0.6-1.7)
Presence of Septations (%)	13(8-21)	95 (84-99)	89 (67-98)	27 (20-35)	2.9 (0.7-12)
Anechoic Effusion Resulting in Transudate	71 (55-84)	29 (21-38)	25 (18-34)	75 (60-86)	1.0 (0.8-1.2)

*Table 4. Diagnostic Performance of Ultrasound Score to Predict Exudative Effusions (Video Only)*

	Sensitivity (95% CI)	Specificity (95% CI)	PPV (95% CI)	NPV (95% CI)	Positive LR (95% CI)
Nonzero sonographic score (%)	37 (27-48)	68 (46-85)	80 (65-91)	23 (14-36)	1.1 (0.6-2.2)
Presence of Septations (%)	19 (11-28)	96 (80-99)	94 (73-99)	24 (16-34)	4.7 (0.66-33.8)
Anechoic Effusion Resulting in Transudate	68 (46-85)	37 (27-85)	23 (14-34)	80 (56-91)	1.1 (0.8-1.5)

Sensitivity of a nonzero sonographic score for an exudate was 29% (95% CI 21-38%), while specificity was 71.4% (95% CI 55-84%). The positive likelihood ratio (LR) of an exudate being present on a thoracentesis following a nonzero sonographic score was 1.0 (95% CI 0.6-1.7). The presence of septations had a specificity of 95.2% (95% CI 84-99%) for an exudate. The positive LR of an exudate being present on thoracentesis following TUS findings of septations was 2.85 (0.7-12). After excluding patients for whom only still images were available, the specificity, PPV and positive likelihood ratio of the presence of septations increased to 96% (95% CI 80-99), 94% (95% CI 73-99), and 4.7 (95% CI 0.66-33.8) respectively. The diagnostic performance of TUS to predict transudative and exudative effusions are described in Table 3 and Table 4. Patient conditions including as decompensated heart failure, hepatohydrothorax, and malignancy had wide distributions of pleural diagnosis (Tables 5-7).

There was disagreement between the two primary raters in 18 (11%) cases, most commonly due to assessment of the presence of gain artifacts. Overall agreement between the two raters was substantial with a Cohen's kappa of 0.75. Overall agreement between the two raters between TUS videos only was almost perfect with a Cohen's kappa of 0.81. Interrater reliability was decreased between the two raters when only ultrasound still images were used with a Cohen's kappa of 0.67.

## Discussion

In a cohort of 166 pleural effusions, the presence of septations on TUS evaluation was highly specific for exudative fluid, though not predictive for a specific etiology. Nonseptated echoes in the pleural space was only moderately specific, and not sensitive for exudative fluid. Finding anechoic fluid did not reliably differentiate transudative or exudative fluid.

Previous studies have examined the relationship between ultrasound images and pleural fluid characteristics. Yang et al. evaluated a cohort of 320 patients with pleural effusions, finding high sensitivity, but poor specificity of anechoic effusions for transudative effusions [6]. In our study, we found anechoic effusions to be only moderately sensitive for transudative effusions. While 23 (21%) of patients had heart failure or hepatohydrothorax as the etiology of their pleural effusion, half of these patients had exudative effusions. Although the chemical analysis of these pleural effusions were exudative, these effusions may have been transudates that became concentrated into exudates through diuresis and may explain the low sensitivity of anechoic effusions for transudates in our population. Unlike findings in subsequent studies, patients with any pleural complexity had exclusively exudative effusions. Svigals et al. described 66 patients with parapneumonic effusions, finding TUS had sensitivity of 69.2% (95% CI 48.2% to 85.7%) and specificity of 90.0% (95% CI 76.3% to 97.2%) [8]. In a cohort of 126 patients with transudative pleural effusions, Chen et al. found that an anechoic pattern was present in 45%



**Table 5. Distribution of Pleural Diagnoses by Thoracic Ultrasound in Patients with Decompensated Heart Failure**

	Transudate	Exudate	Total
Anechoic	4	4	8
Complex, non-septated	1	2	3
Complex, septated	0	0	0
Homogenously echogenic	0	0	0
Total	8	3	11

**Table 6. Distribution of Pleural Diagnoses by Thoracic Ultrasound in Patients with Hepatohydrothorax**

	Transudate	Exudate	Total
Anechoic	6	7	13
Complex, non-septated	5	1	6
Complex, septated	1	2	3
Homogenously echogenic	0	0	0
Total	12	10	22

**Table 7. Distribution of Pleural Diagnoses by Thoracic Ultrasound in Patients with Malignancy**

	Transudate	Exudate	Total
Anechoic	7	50	57
Complex, non-septated	0	14	14
Complex, septated	1	8	9
Homogenously echogenic	0	1	1
Total	8	73	81

(57/127), while a complex nonseptated pattern in 55% (70/127); transudative fluid was never complex septated or homogenously echogenic [11]. Asciak et al. found that of 85 patients with echogenic effusions, six (7.1%) had transudates, leaving the specificity of echogenicity to identify exudates from transudates as 57.1% [9]. A recent evaluation of 300 pleural effusions in 285 patients found that detection of septations or homogenous complexity was 94% specific and carried a 96% positive predictive value for exudative fluid. Additionally, anechoic fluid did not reliably predict the presence of transudative fluid<sup>7</sup>. Outside of a much lower sensitivity (21% vs 70%) for complex effusions our findings support the conclusions of that study, in a different patient population at a different center.

These findings support and extends existing primary literature in several ways. The performance characteristics generally mirrored that of the most recent evaluation of TUS by Shkolnik et al, supporting the high specific and PPV of septations for exudative fluid, though

the confidence interval for the positive LR cross 1.0 and are wide [7]. Additionally, the present study was enriched in patients with known malignancy. Performance characteristics of TUS did not differ from a broader cohort in this subgroup, suggesting diagnostic thoracentesis would likely be required for definitive diagnosis of a new pleural effusion in a patient with known malignancy.

The study also highlights the importance of video images for interpretation with increases of both testing characteristics and inter-rater agreement when compared to evaluation with still images. When disagreement occurred between the two primary raters, it was most frequently in still images and often due to assessment of the presence of gain artifacts.

Future studies should focus further standardization of machine settings and scanning protocols. Additionally, our study highlights the need to identify other ultrasound imaging characteristics to improve diagnostic performance. Studies have identified the presence of pleural masses, pleural thickening >1 cm, pleural nodularity and diaphragmatic thickening >7 mm as TUS findings that are highly suggestive of malignant pleural effusion disease [12,13]. Incorporation of other imaging features with the standard pleural fluid image characterization may increase diagnostic performance.

Limitations of our study include describing only a single center, which may limit generalizability, though had similar findings to other studies at other centers. Certain pleural fluid diagnoses may have been more common at our institution and less common at other locations. Some patients in our series did not have a complete set of diagnostic tests reviewed for the study because the tests were ordered by the physician responsible for the patient's care at the time of thoracentesis. This may have led to some selection bias (for example pleural effusions not requiring fluid analysis because it was thought to be due to heart failure). Lastly, while there was high degrees of inter-rater reliability, it was not perfect. This highlights the potential need for strict criteria for classification of effusion, and potentially the limitation of retrospective video review in the absence of a standardized scanning methodology. Though used by experienced operators that frequently work together, machine settings including gain were not always consistent. Insufficient gain could inappropriately characterize a complex, nonseptated effusion as anechoic while with too much gain faint artifacts will make anechoic fluid appear to have internal echoes [14]. An expert may be able to differentiate the patterns of artifact overgain from actual echogenicity based on the movement of echoes within the fluid, but this has not been tested in published literature. Ideally, gain would be standardized using a known echogenic quantity such as the blood inside a vessel, but those are

not always visible in the same window as a pleural effusion. Similarly, image acquisition is operator dependent. While we evaluated rater inter-rater agreement, examining differences between ultrasound acquisition by user may have added value.

## Conclusion

TUS is already part of the standard of care in thoracentesis and using that information beyond simply marking the puncture site can add value. Our analysis suggests that anechoic pleural fluid images do not reliably distinguish between transudative and exudative fluid. While features such as complex septation or homogenous echogenicity are highly supportive of exudative fluid, further research is needed to identify other features that would increase diagnostic accuracy.

## Disclosures

Dr. Cameron Baston receives royalty payments from McGraw Hill for a textbook on POCUS.

## References

1. Mattison LE, Coppage L, Alderman DF, Herlong JO, Sahn SA. Pleural effusions in the medical ICU: prevalence, causes, and clinical implications. *Chest*. 1997;111(4):1018-1023. doi:10.1378/chest.111.4.1018
2. Light RW. Pleural Effusions. *Medical Clinics of North America*. 2011;95(6):1055-1070. doi:10.1016/j.mcna.2011.08.005
3. Grimberg A, Shigueoka DC, Atallah AN, Ajzen S, Iared W. Diagnostic accuracy of sonography for pleural effusion: systematic review. *Sao Paulo Med J*. 2010;128(2):90-95. doi:10.1590/s1516-31802010000200009
4. Millington SJ, Koenig S. Better With Ultrasound: Pleural Procedures in Critically Ill Patients. *Chest*. 2018;153(1):224-232. doi:10.1016/j.chest.2017.06.043
5. Gordon CE, Feller-Kopman D, Balk EM, Smetana GW. Pneumothorax following thoracentesis: a systematic review and meta-analysis. *Arch Intern Med*. 2010;170(4):332-339. doi:10.1001/archinternmed.2009.548
6. Yang PC, Luh KT, Chang DB, Wu HD, Yu CJ, Kuo SH. Value of sonography in determining the nature of pleural effusion: analysis of 320 cases. *AJR Am J Roentgenol*. 1992;159(1):29-33. doi:10.2214/ajr.159.1.1609716
7. Shkolnik B, Judson MA, Austin A, et al. Diagnostic Accuracy of Thoracic Ultrasonography to Differentiate Transudative From Exudative Pleural Effusion. *Chest*. 2020;158(2):692-697. doi:10.1016/j.chest.2020.02.051
8. Svigals PZ, Chopra A, Ravenel JG, Nietert PJ, Huggins JT. The accuracy of pleural ultrasonography in diagnosing complicated parapneumonic pleural effusions. *Thorax*. 2017;72(1):94-95. doi:10.1136/thoraxjnl-2016-208904
9. Asciak R, Hassan M, Mercer RM, et al. Prospective Analysis of the Predictive Value of Sonographic Pleural Fluid Echogenicity for the Diagnosis of Exudative Effusion. *Respiration*. 2019;97(5):451-456. doi:10.1159/000496153
10. Light RW, Macgregor MI, Luchsinger PC, Ball WC. Pleural Effusions: The Diagnostic Separation of Transudates and Exudates. *Annals of Internal Medicine*. 1972;77(4):507-513. doi:10.7326/0003-

4819-77-4-507

11. Chen H-J, Tu C-Y, Ling S-J, et al. Sonographic Appearances in Transudative Pleural Effusions: Not Always an Anechoic Pattern. *Ultrasound in Medicine & Biology*. 2008;34(3):362-369. doi:10.1016/j.ultrasmedbio.2007.09.009
12. Görg C, Restrepo I, Schwerk WB. Sonography of malignant pleural effusion. *Eur Radiol*. 1997;7(8):1195-1198. doi:10.1007/s003300050273
13. Qureshi NR, Rahman NM, Gleeson FV. Thoracic ultrasound in the diagnosis of malignant pleural effusion. *Thorax*. 2009;64(2):139-143. doi:10.1136/thx.2008.100545
14. Baston CM, Panebianco N. To Tap or Not To Tap (a Pleural Effusion), That Is the Question. *CHEST*. 2020;158(2):451-452. doi:10.1016/j.chest.2020.04.004

# Development and Evaluation of Resident-Championed Point-of-Care Ultrasound Curriculum for Internal Medicine Residents

Leila Haghighat, MD<sup>1\*</sup>; Hayley Israel, MD<sup>2\*</sup>; Eric Jordan, MD<sup>3\*</sup>; Ethan L. Bernstein, MD<sup>3</sup>; Marilyn Varghese, MD<sup>4</sup>; Benjamin M. Cherry, MD<sup>3,5</sup>; Reinier Van Tonder, MD<sup>6</sup>; Shyoko Honiden, MD<sup>2</sup>; Rachel Liu, MD<sup>6</sup>; Christopher Sankey, MD<sup>3</sup>

\*These authors contributed equally to the work

(1) Division of Cardiology, Department of Internal Medicine, University of California San Francisco, San Francisco, California, USA

(2) Section of Pulmonary, Critical Care and Sleep Medicine, Department of Internal Medicine, Yale University School of Medicine, New Haven, Connecticut, USA

(3) Section of General Internal Medicine, Department of Internal Medicine, Yale University School of Medicine, New Haven, Connecticut, USA

(4) Division of Cardiology, Department of Medicine, Beth Israel Deaconess Medical Center and Harvard Medical School, Boston Massachusetts, USA

(5) VA Connecticut Health System West Haven Campus, West Haven, Connecticut, USA

(6) Department of Emergency Medicine, Yale University School of Medicine, New Haven, Connecticut, USA

## Abstract

**Introduction:** Point-of-care ultrasound (POCUS) is a powerful clinical tool that has seen widespread adoption, including in Internal Medicine (IM), yet standardized curricula designed by trained faculty are scant. To address the demand for POCUS education at our institution, we created a resident-championed curriculum with support from skilled faculty across multiple specialties. Our objective was to teach postgraduate year (PGY)-3 IM residents the basics of POCUS for evaluation of the pulmonary, cardiac, and abdominal systems through resident-developed workshops. The goal of acquisition of these skills was for resident education and to inform decisions to pursue further patient testing. **Methods:** Three half-day workshops were created to teach residents how to obtain and interpret ultrasound images of the pulmonary, cardiac, and abdominal systems. Workshops were comprised of didactic teaching and practical ultrasound instruction with expert supervision of clinicians within and outside of IM. Residents were asked to complete a written survey before and after each workshop to assess confidence, knowledge, and likelihood of future POCUS use. **Results:** Across the three workshops (pulmonary, cardiac, and abdominal), 66 sets of pre- and post-workshop surveys (32 pulmonary, 25 cardiac, and 9 abdominal) were obtained and analyzed. Confidence in and knowledge regarding POCUS use increased significantly across all three workshops. Likelihood of future use increased in the cardiac workshop. **Conclusions:** We implemented a resident-championed POCUS curriculum that led to improved attitudes and increased knowledge of POCUS for PGY-3 IM residents.

## Background

In the last decade, advances in technology have made ultrasound technology more affordable, portable, and user-friendly. Portable ultrasound has become a valuable addition to the bedside evaluation of patients. An increasing number of clinicians across medical specialties have incorporated point-of-care ultrasound (POCUS) into practice, and professional societies have begun to codify its use. POCUS has been added to the Accreditation Council for Graduate Medical Education (ACGME) core competencies for Emergency Medicine, and the American College of Physicians (ACP) has acknowledged the important role of POCUS in Internal Medicine (IM) [1-2]. The Society of Hospital Medicine (SHM) similarly published a position statement in 2019 for Hospital Medicine specialists who use POCUS [3].

Despite the proliferation of POCUS in clinical practice, the

prevalence of formal POCUS teaching within United States IM training programs is less frequent, with only 25-31% of residencies reporting a formal curriculum [4-5]. A survey of program directors in 2018 found that fewer than half of IM residents in the US will have trained at a program with a POCUS curriculum [6]. The implementation of POCUS training at the level of undergraduate medical education appears to exceed that of graduate medical education, as evidenced by a 2012 survey of US medical schools in which 62% of responding medical schools reporting having POCUS curricula [7]. This discrepancy between training at the undergraduate and graduate level implies that many trainees are experiencing a decrease in POCUS education as they advance in their training, and that there is a need to increase the number of graduate programs offering curricula to make up for this difference.

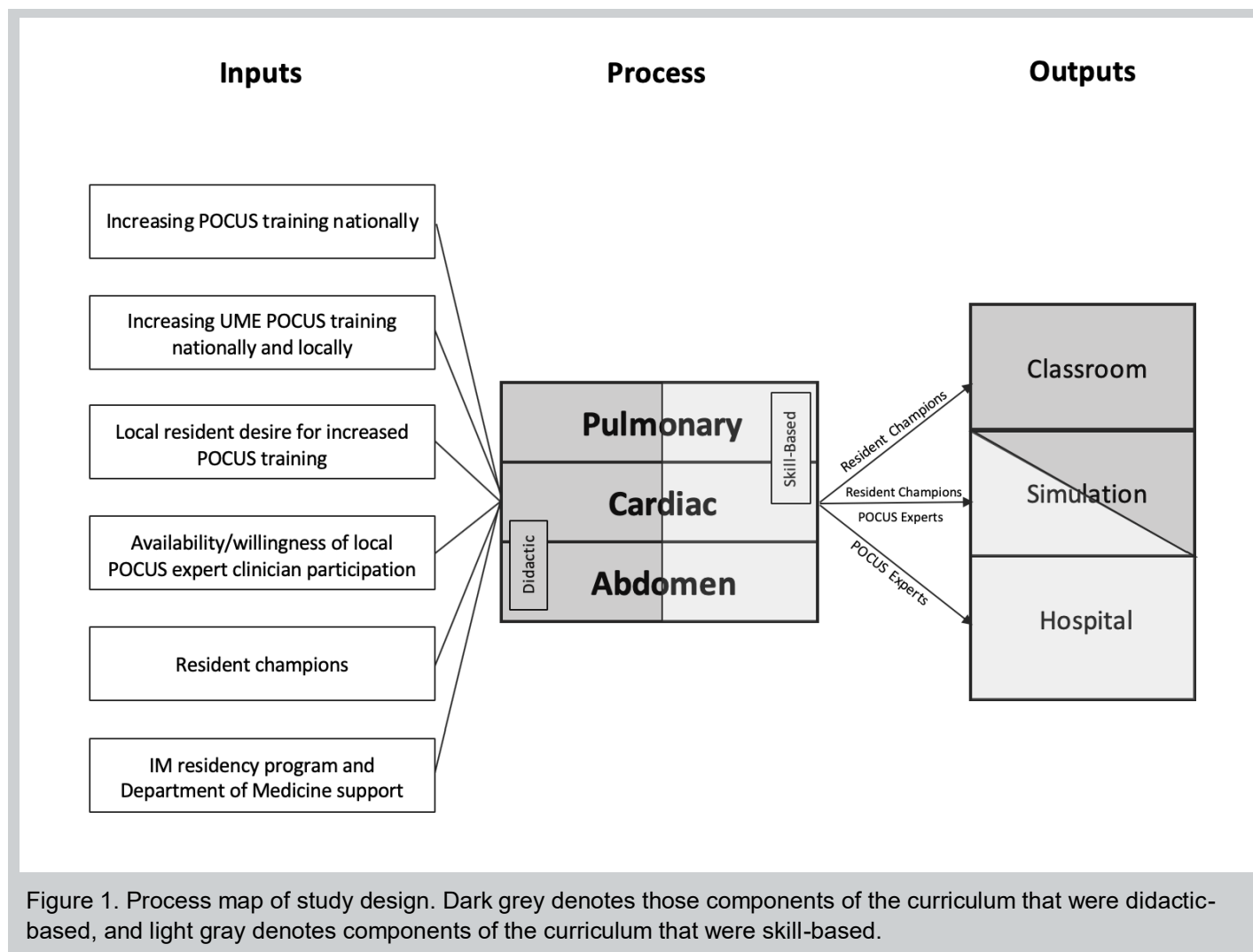


Figure 1. Process map of study design. Dark grey denotes those components of the curriculum that were didactic-based, and light gray denotes components of the curriculum that were skill-based.

In a 2010 needs assessment of medical students and IM residents, over 95% of respondents believed POCUS was useful and desired more formal training [8]. Different formats and approaches have been described for building POCUS curricula within IM programs which generally emphasize the elements of having ultrasound machines, hands-on “practical” education, and didactics facilitated by dedicated POCUS faculty [9-14]. LoPresti and colleagues have also highlighted the importance of ongoing competence assessments and quality assurance [15]. The principal reason cited by IM programs for the lack of POCUS education is a lack of trained instructors [16].

Resident-championed educational initiatives have been utilized for multiple facets of post-graduate medical education. The types of skills taught have included performing physical exam maneuvers, writing handoffs, and managing patients in the critical care setting [17-19]. After an extensive literature search, it appears no such initiatives have been previously reported for POCUS.

We demonstrate here a resident-driven POCUS

curriculum that yields measurable gains in resident POCUS education, without the need for prohibitive expert faculty time.

## Methods

### Subjects

Forty postgraduate year (PGY)-3 IM residents at Yale New Haven Hospital, which is associated with the Yale School of Medicine, during the 2018-2019 academic year were considered for this study. All but the four residents involved in the design and implementation of this study were included.

### Ultrasound Course

Residents in the Yale New Haven Hospital IM residency program rotated through the same outpatient clinic for two weeks at a time, repeated every six weeks, as part of an existing ambulatory curriculum. One half-day during each week of clinic was reserved for formal didactics, at which time our curriculum was delivered. Residents were divided into four “blocks”, which refers to the recurring two-week time period comprising a subset of residents



Table 1. Summary of educational content delivered in each of 3 POCUS sessions.

POCUS Course Section	Abdominal	Cardiac	Pulmonary
Educational Content	<ul style="list-style-type: none"> <li>• Ultrasound physics</li> <li>• Probe selection</li> <li>• Scanning technique</li> <li>• Machine Interface</li> </ul>		
	<ul style="list-style-type: none"> <li>• IVC assessment</li> <li>• Evaluation of hydronephrosis</li> <li>• Evaluation of urinary retention</li> </ul>	<ul style="list-style-type: none"> <li>• Parasternal long-axis view</li> <li>• Parasternal short-axis view</li> <li>• Apical 4-chamber view</li> <li>• Subxiphoid view</li> <li>• Evaluation of pericardial effusion</li> <li>• Evaluation of ejection fraction</li> <li>• Evaluation of right-heart strain</li> <li>• Evaluation of aortic root dilatation</li> </ul>	<ul style="list-style-type: none"> <li>• A-lines</li> <li>• B-lines</li> <li>• Evaluation of pneumothorax</li> <li>• Evaluation of pleural effusion</li> <li>• Evaluation of pulmonary edema</li> </ul>

that always rotate together during their ambulatory time. This allowed for the same two-week curriculum to be repeated for an additional six weeks to facilitate participation of all residents.

The ultrasound training was divided into three components: the pulmonary, cardiac, and abdominal systems. Curriculum content was selected to cover material that learners would not encounter elsewhere; for example, residents learn to use POCUS for procedures during Intensive Care Unit rotations, so procedural POCUS was not included. Vascular and musculoskeletal evaluation was not emphasized due to time constraints. Teaching sessions were conducted during educational half-days from October to November 2018, December 2018 to January 2019, and February to March 2019, respectively, such that each resident received instruction in each component of the course once. Every component included a one-hour didactic, followed by three hours of skill-based hands-on practice that was performed at the Yale Center for Medical Simulation or designated physical examination practice rooms at the Yale School of Medicine. Machines used for hands-on sessions included the cart-based Sparq system (Philips, Andover, MA), tablet-based Butterfly iQ (Butterfly Network, Inc., Guilford, CT), and tablet-based Lumify (Philips, Andover, MA) devices.

Four PGY-3 IM residents with prior experience in POCUS developed the curriculum content and functioned as resident champions. Resident champion preparation consisted of completing a two-week ultrasound elective with Emergency Medicine faculty or attending a POCUS workshop at a national meeting. Expert POCUS supervisors were identified among clinicians within IM, Pulmonary/Critical Care Medicine, Cardiology, and

Emergency Medicine. These faculty reviewed didactic content and taught image acquisition skills during the practical portion. A total of 18 different clinicians contributed their time and expertise, with commitments ranging from two to twenty hours per individual. For each topic component, one of the resident champions delivered the didactic portion of the session to their resident colleagues. In the skill-based portion conducted in the Yale New Haven Hospital Center for Medical Simulation and Yale School of Medicine, residents received practical experience by performing scans on one another. A subset of residents volunteered to be scanned as a model by their peers, and these residents provided verbal consent to do so. The skill-based portion started with a faculty champion demonstrating correct probe positioning and motions, after which the faculty champion would observe each resident in finding the same image, with in moment feedback to correct technique if needed.

A summary of educational content covered throughout the course is included in Table 1. A process map of the design of our POCUS course, with specific attention to where resident champions were involved, is depicted in Figure 1.

#### *Learner Assessment*

A 10-question survey written by the resident section champion was administered before the start of the didactic (Supplementary Figure S1). The survey comprised of questions regarding confidence, knowledge, and likelihood of POCUS use in future clinical practice. Confidence and likelihood of use were assessed on a self-reported Likert scale, and knowledge was assessed using multiple-choice questions. The same survey was repeated at the conclusion of the skill-based curricular

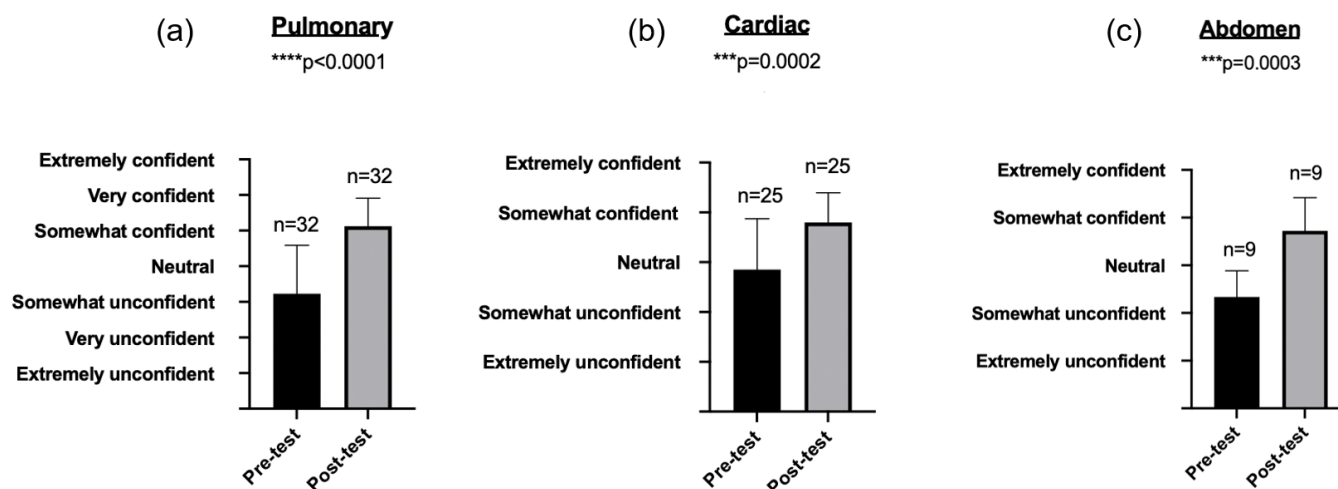


Figure 2. Pre- and post- assessments of resident confidence in POCUS. Confidence rose in a statistically significance manner across the cardiac ( $p=0.002$ ), pulmonary ( $p<0.0001$ ), and abdomen ( $p=0.0003$ ) sections.

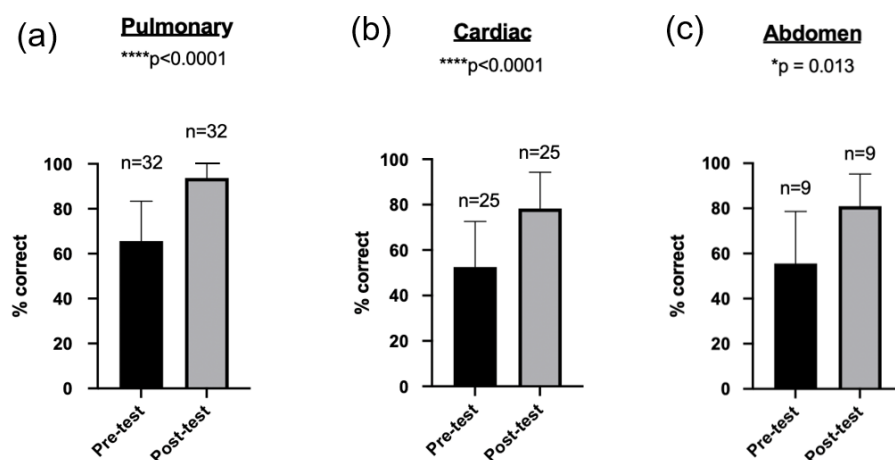


Figure 3. Pre- and post-assessments of accuracy on knowledge-based questions about POCUS. Accuracy rose in a statistically significance manner across all sections. (a) Mean difference before and after intervention  $28.13\% \pm 3.56\%$  (95% CI: 21.01% to 35.24%,  $p < 0.0001$ ). (b) Mean difference before and after intervention  $25.71\% \pm 8.14\%$  (95% CI: 15.38% to 36.05%,  $p < 0.0001$ ). (c) Mean difference before and after intervention  $26.98\% \pm 11.41\%$  (95% CI: 2.22% to 44.58%,  $p = 0.013$ ).

component. There was no formal assessment of the hands-on scanning component.

#### Statistical Analysis

Pre- and post-intervention surveys were compared using t-tests on Prism 8 software (GraphPad, San Diego, CA), with significance considered  $p < 0.05$ .

#### IRB Exemption

The study methods and assessment instruments were submitted to the Yale University Institutional Review Board (IRB). The study was determined to be exempt from IRB review. Exemption was granted 5/23/2018 for protocol number 2000023277.

## Results

Pre- and post-test surveys were collected before and after each session. There were 32 residents present for the pulmonary sessions and 32 out of 32 (100%) completed both pre- and post- surveys. A total of 35 residents attended the cardiac sessions and 25 out of 35 (71.4%) completed both surveys. Nine total residents attended the abdominal sessions and nine out of nine (100%) completed both surveys. Attendance at the abdominal sessions was limited by scheduling conflicts.

Confidence in POCUS skills improved after all sessions (Figure 2). For the pulmonary section, confidence improved from “somewhat unconfident” to “somewhat confident” ( $p < 0.0001$ ). For the cardiac section, residents

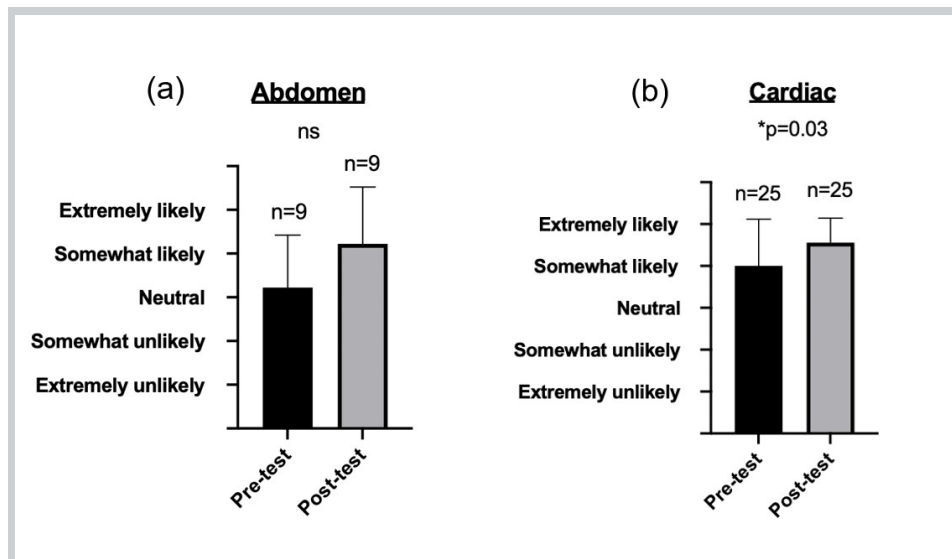


Figure 4. Pre- and post-assessments of resident likelihood of POCUS use. Confidence rose in a statistically significance manner in the cardiac ( $p=0.03$ ) but not abdomen ( $p=0.11$ ) sections.

prior to the session reported “neutral” confidence, which improved to “somewhat confident” after the session ( $p=0.0002$ ). For the abdominal section, residents went from being “somewhat unconfident” prior to the session to “somewhat confident” following the session ( $p=0.0003$ ).

Knowledge assessment improved after all sessions, as measured by 10-question surveys (Figure 3). In the pulmonary section, average percentage correct before the session was  $65.6\% \pm 3\%$  compared to  $93.8\% \pm 2\%$  after the session ( $p<0.05$ ). In the cardiac section, the average percentage correct before the session was  $52.6\% \pm 4\%$  compared to  $78.3\% \pm 5\%$  after the session ( $p<0.05$ ). In the abdominal section, the average percentage correct before the session was  $55.6\% \pm 8\%$  compared to  $81.0\% \pm 5\%$  after the session ( $p<0.05$ ).

Likelihood of use increased only in the cardiac section (Figure 4). For this section, residents were on average “somewhat unlikely” to use POCUS before the session and “extremely likely” after ( $p=0.03$ ). For the abdominal section, residents went from feeling “neutral” to “somewhat likely” ( $p=0.11$ ). Residents were not asked about likelihood of future POCUS use in the survey administered for the pulmonary session.

## Discussion

### Analysis

In this study, we demonstrate the feasible implementation of a resident-championed POCUS curriculum that covered the pulmonary, cardiac, and abdominal systems. The curriculum resulted in statistically significant gains in resident confidence and knowledge regarding POCUS use across all sections, with increased likelihood of use of cardiac POCUS. We believe that ultrasound abilities are best gained through a combination of formal didactics, simulation, and performing educational scans on human subjects as evidenced by the improvement residents

made over a short period of time through our curriculum being set up in this manner. This may serve as a proof-of-concept for other programs who are also looking to develop resident-designed POCUS curricula.

### Strengths

One of the major strengths of this curriculum is that it was designed and implemented by resident champions, which was beneficial for engagement and participation of participants. Champions selected the scope and learning objectives for each session and created the educational content of each presentation. This peer-teaching and “bottom-up” approach to creating a longitudinal POCUS curriculum was supplemented with expert clinicians donating their time and skills in a sustainable manner. In total, 18 clinicians from multiple departments each contributed between two and twenty hours of support.

The timing of the course allowed us to reach a large number of housestaff, comprising the entire cohort of senior IM residents in our program. Additionally, the skill-based sessions resulted in interdepartmental collaboration, given that faculty and fellows from multiple specialties were present at the same time. This laid the foundation for ongoing collaborative educational efforts, such as the creation of ultrasound electives for IM residents on the hospitalist and critical care services.

### Challenges/Areas for Improvement

There are a number of limitations to this study that allow for future areas of improvement. Lack of consistency of questions on the surveys of component sections was a drawback, specifically the omission of a question asking about likelihood of future POCUS use on the pulmonary survey. Another major limitation is the lack of data from the abdominal workshops, which limits our ability to draw conclusions about one third of the curriculum. Survey completion for the cardiac sessions was only 71% which

limits the generalizability of these results, however even with this limited response rate statistically significant gains in knowledge, confidence, and likelihood of future POCUS use were seen. There is additionally a need to repeat assessment of knowledge and attitudes after some time has elapsed since participation in the sessions. Lack of this information limits our ability to comment on retention of material from the workshops over time. A final constraint is lack of assessment of subsequent POCUS use for workshop participants.

Another limitation of this study and the curriculum described is the absence of ongoing quality assurance and competence assessment, including that of hands-on scanning technique. For this curriculum to thrive, processes will need to be put in place for residents to store their images and receive ongoing feedback from POCUS faculty beyond the initial workshops.

### *Future directions*

The curriculum at present only involves PGY-3s because of restraints on available time within the larger IM curriculum. Ideally, PGY-3s will teach acquired POCUS skills to junior learners in a similar fashion to how physical diagnosis skills are traditionally taught. We hope to continue to increase the time allowed for each of the component POCUS sessions within the structured educational time for residents of all PGY years.

At present, we are beginning to evaluate our curriculum at levels one and two of the Kirkpatrick Model for evaluating training programs (levels one and two being attitude and knowledge), but our hope is that in the near future we will evaluate at level three: behavioral change [20]. Level four (translation to outcomes for patient care) remains an aspirational goal at present. As residents continue to gain POCUS skills in an educational setting, rigorous quality control and assessments of competence prior to allowing residents to use POCUS for direct patient care will be necessary. Finally, as future goals we hope to demonstrate long term retention of knowledge, formal grading of image acquisition and quality, and standardized assessments through the use of observed structured clinical examinations (OSCEs).

### **Conclusion**

Overall, we demonstrate the feasible implementation of a resident-championed POCUS curriculum and the acquisition of improved attitudes and increased knowledge for IM PGY-3 residents.

### **Conflict of Interest**

All authors declare that they have no conflict of interest.

### **References**

1. American College of Emergency Physicians. Ultrasound guidelines: emergency, point-of-care and clinical ultrasound guidelines in medicine. *Ann Emerg Med* 2017;69: 27-54.
2. American College of Physicians. Point of care ultrasound (POCUS) for internal medicine. <https://www.acponline.org/meetings-courses/focused-topics/point-of-care-ultrasound-pocus-for-internal-medicine/acp-statement-in-support-of-point-of-care-ultrasound-in-internal-medicine>. Accessed July 5, 2019.
3. Soni NJ, Schnobrich D, Mathews BK et al. Point-of-care ultrasound for hospitalists: a position statement of the Society of Hospital Medicine. *J Hosp Med* 2019. 14: e1-e6.
4. Reaume M, Siuba M, Wagner M et al. Prevalence and scope of point-of-care ultrasound education in internal medicine, pediatric, and medicine-pediatric residency programs in the United States. *J Ultrasound Med* 2018. 38(6):1433-1439
5. Schonbrich DJ, Gladding S, Olson APJ et al. Point-of-care ultrasound in internal medicine: a national survey of educational leadership. *J Grad Med Educ* 2013. 5(3):498-502
6. Kimura BJ, Amundson SA, Phan JN. Observations during development of an internal medicine residency training program and cardiovascular limited ultrasound education. *J Hosp Med* 2012. 7(7): 537-42.
7. Bahner DP, Goldman E, Way D, et al. The state of ultrasound education in U.S. medical schools: results of a national survey. *Acad Med* 2014. 89(12): 1681-1686.
8. Kessler C and Bhandarkar S. Ultrasound training for medical students and internal medicine residents—A needs assessment." *J Clin Ultrasound* 2010. 38: 401-8.
9. Smith CJ, Matthias T, Beam E, et al. Building a bigger tent in point-of-care ultrasound education: a mixed-methods evaluation of interprofessional, near-peer teaching of internal medicine residents by sonography students. *BMC Med Ed* 2018. 18: 321.
10. Anstey JE, Jensen TP, Afshar N. Point-of-care ultrasound needs assessment, curriculum design, and curriculum assessment in a large academic internal medicine residency program. *South Med J* 2018. 111(7): 444-448.
11. Galen BT and Conigliaro RL. The Montefiore 10: a pilot curriculum in point-of-care ultrasound for internal medicine residency training. *J Grad Med Educ* 2018. 10(1): 110–111.
12. Clay RD, Lee EC, Kurtzman MF, et al. Teaching the internist to see: effectiveness of a 1-day workshop in bedside ultrasound for internal medicine residents. *Crit Ultrasound J* 2016. 8(1): 11.
13. Skalski JH, Elrashidi M, Reed DA, et al. Using standardized patients to teach point-of-care ultrasound-guided physical examination skills to internal medicine residents. *J Grad Med Educ* 2015. 7(1):95-7.
14. Schonbrich D, Olson APJ, Duran-Nelson A. Feasibility and acceptability of a structured curriculum in teaching procedural and basic diagnostic ultrasound skills to internal medicine residents. *J Grad Med Educ* 2013. 5(3):493-497 .
15. LoPresti, C.M., Schnobrich, D.J., Dversdal, R.K. et al. A road map for point-of-care ultrasound training in internal medicine residency. *Ultrasound J* 2019. 11:10.
16. Bhagra A, Tierney DM, Sekiguchi H, et al. Point-of-care ultrasonography for primary care physicians and general internists. *Mayo Clin Proc* 2016. 91 (12): 1811-1827.
17. Wijeratne DT, Srivastava S, Chan B, et al. Sustainability of physical exam skills in a resident-led curriculum in a large internal medicine program with competency based medical education. *Can Med Educ J* 2018. 9(4): e78-92.
18. Hill E, Cartabuke RH, Mehta N, et al. Resident-led handoffs training for interns: online versus live instruction with subsequent skills assessment. *Am J Med* 2017. 130 (10): 125-130.
19. Mathai SK, Miloslavsky EM, Contreras-Valdes FM, et al. How we implemented a resident-led medical simulation curriculum in a large internal medicine residency program. *Med Teach* 2014. 36 (4): 279-83.
20. Kirkpatrick DL and Kirkpatrick JD. *Evaluating Training Programs: the Four Levels*. Third edition. Berrett-Koehler Publishers: 2006.



# Lung Ultrasound to Monitor Disease Severity and Aid Prognostication in COVID-19 Pneumonia: A Retrospective Analysis of Serial Lung Ultrasound Assessments

Matthew Llewelyn Gibbins, MBChB DTMH FRCA FFICM<sup>1</sup>; Quentin Otto, MA MB BChir DiMM<sup>2</sup>; Paul Adrian Clarke, BM BSc MRCP FRCA FFICM<sup>1</sup>; Stefan Gurney, MB BS MD (Res) FRCA FFICM<sup>1</sup>

(1) Anaesthetic and Intensive Care Medicine Consultant, Bristol Royal Infirmary (BRI), Bristol, BS2 8HW

(2) Acute Care Common Stem trainee, BRI, Bristol, BS2 8HW

## Abstract

**Background:** The aim of this retrospective analysis was to assess if serial lung ultrasound assessments in patients with COVID-19 pneumonia, including a novel simplified scoring system, correlate with  $\text{PaO}_2\text{:FiO}_2$  ratio, as a marker of disease severity, and patient outcomes. **Methods:** Patients treated for COVID-19 pneumonia in a tertiary intensive care unit who had a lung ultrasound assessment were included. Standardised assessments of anterior and lateral lung regions were prospectively recorded. A validated lung ultrasound score-of-aeration and a simplified scoring system based on the number of disease-free lung regions were correlated with:  $\text{PaO}_2\text{:FiO}_2$  ratio, successful weaning from mechanical ventilation, and status (alive or dead) at discharge. MedCalc© statistical software was used for statistical analysis. **Results:** 28 patients (109 assessments) were included. Correlation was seen between score-of-aeration and  $\text{PaO}_2\text{:FiO}_2$  ratio ( $r = -0.61$ ,  $p < 0.0001$ ) and between the simplified scoring system and  $\text{PaO}_2\text{:FiO}_2$  ratio ( $r = 0.52$ ,  $p < 0.0001$ ). Achieving a score-of-aeration of  $\leq 9/24$  or  $\geq 2$  disease-free regions was associated with successful weaning from mechanical ventilation and survival to ICU discharge (accuracy of 94% and 97% respectively). **Conclusion:** Retrospective analysis from this small cohort of patients demonstrates that scores-of-aeration and a simplified scoring system based on the number of disease-free antero-lateral regions from serial LUS assessments correlate with  $\text{PaO}_2\text{:FiO}_2$  ratio as a marker of disease severity in patients with COVID-19 pneumonia. In addition, lung ultrasound may help identify patients who will have favourable outcomes.

## Background

Point of care Lung Ultrasound (LUS) is validated in the diagnosis and monitoring of lung pathology [1–3] and has proven a useful imaging modality during the SARS-CoV-2 (COVID-19) pandemic [4]. The peripheral distribution of pathological changes within the lungs facilitate detection by LUS [5] and early reports demonstrate good correlation with computerised tomography (CT) and a higher diagnostic yield than chest x-ray [4,6,7]. Lung Ultrasound has additional advantages over other imaging modalities. These include immediate availability for point of care serial assessments, low cost, and its safety profile for both the operator and patient [4].

The characteristic LUS features of COVID-19 pneumonia that have been described include; pleural line irregularities with subpleural consolidation, extensive ‘B-lines’ (vertical artefacts extending from the pleura) which affect most lung regions, and in severe cases dependant consolidation. Pleural effusions are uncommon and the reappearance of ‘A-lines’ (horizontal ‘reverberation’ artefacts) has been noted on resolution [6–9].

During the COVID-19 pandemic reports have described

the use of LUS in the diagnosis of COVID-19 pneumonia and for assessment of its severity and for assessing response to interventions such as prone positioning, recruitment manoeuvres and diuresis [4,6,7,9]. However, due to the need for rapid dissemination of experience and information, publications have been limited to narrative reviews or case studies with few patients and more importantly, limited comment on longitudinal data [10].

The primary aim of this retrospective analysis was to establish whether findings from serial LUS assessments of patients admitted to critical care with COVID-19 pneumonia, including a novel simplified scoring system, correlate with  $\text{PaO}_2\text{:FiO}_2$  ratio as marker of disease severity. Our secondary aim was to establish whether LUS findings correlate with patient outcomes.

## Methods

This study has been reported in accordance with the STROBE guidelines for observational studies (Figure S1) [11].

Pragmatic LUS assessment formed part of the standard care of patients with respiratory failure in our ICU during the COVID-19 pandemic.

A retrospective review of patients admitted to our tertiary ICU with respiratory failure during the global COVID-19 pandemic was performed. Patients with a confirmed diagnosis of COVID-19 pneumonia via polymerase chain reaction (PCR) from mucosal swabs (Cepheid Xpert Xpress SARS-CoV-2 assay) and a documented LUS assessment were included. Any patient with a high clinical suspicion and treated for COVID-19 despite negative PCR were also included. Patients were followed up until discharge from the ICU.

Patients had a LUS assessment as soon as practical following admission to ICU, and at non-standardised intervals thereafter. The timings of assessments were determined pragmatically dependant on patient progress, availability of trained operators, patient condition, patient position and clinical questions relevant to their care.

Serial LUS assessments were performed by the first author (MG, accredited in LUS through the Intensive Care Society of the United Kingdom) or by one of seven additional operators and archived. All images, scores and findings from archived assessments were ratified by the first author retrospectively. Assessments were performed using a *Venue Go™* Ultrasound System (GE Healthcare UK, Amersham, UK). A *C1-5 curvilinear* probe and software programs specific to LUS were used for all assessments; '*Lung*' mode optimised image settings to distinguish B-lines, and '*cons/effusion*' mode optimised image settings to identify collapse/consolidation and effusions.

Standardised assessment of the lungs was made by dividing the thorax into 12 regions [12]. All regions were assessed when possible. Each region was then assigned a score based on the worst findings within any 'lung window' during a single respiratory cycle, as follows: normal A-lines or a single B-line = 0,  $\geq 2$  separate B-lines = 1, coalescent B-lines = 2, and collapse/consolidation = 3. Pleural irregularity alone scored 0. The total LUS score of aeration was calculated by the sum of the individual scores and ranged from 0 to 36 [13]. The findings for each region, the total LUS score of aeration, patient position and  $\text{PaO}_2\text{:FiO}_2$  ratio were prospectively entered onto a specific reporting proforma within the patient's electronic clinical records (IntelliSpace Critical Care and anaesthesia, Philips, Guildford UK) when the operator completed each scan. Additional findings were documented as free text, where relevant.

Observations from the initial analysis revealed a potential association between the number of '*disease-free*' regions and clinical improvement/patient outcomes. A disease free regions was defined as: A-lines or a single well-defined B-line in all lung windows within that region (+/- isolated pleural irregularities), leading to an aeration score of zero. The relationship between the number of

disease-free regions and  $\text{PaO}_2\text{:FiO}_2$ /patient outcomes was analysed to establish whether a binary outcome for each lung region ('*disease-free*' or '*disease-present*') could be used as an alternative '*simplified scoring system*' or SSS.

The following baseline patient characteristics were retrieved from the Intensive Care National Audit and Research Centre (ICNARC) database; sex, age, ethnicity, very severe comorbidities, and disease severity scores at admission (APACHE II). The following patient outcomes were recorded; ICU length of stay, whether successful weaning from invasive ventilation was achieved and status (alive or dead) at ICU discharge.

Statistical analysis was performed using MedCalc® statistical software. Confidence intervals for the predictive values are standard logit confidence intervals and confidence intervals for accuracy are "exact" Clopper-Pearson confidence intervals. Correlation was assessed using Spearman's rank correlation coefficient for non-normally distributed data, with 95% confidence intervals and P-values. DeLong et al methodology was used for receiver operating characteristic curve analysis.

## Results

33 patients admitted to our ICU with respiratory failure between March 22<sup>nd</sup> and May 11<sup>th</sup>, 2020 had a LUS assessment documented. 117 LUS assessments were performed - 79 (68%) were performed by the first author and 38 were performed by one of seven additional operators and the findings were ratified retrospectively. 28 patients had a clinical diagnosis of COVID-19 pneumonia and were included in initial analysis. 27/28 patients had a positive PCR from throat or tracheal swabs. The remaining patient was assigned the diagnosis of COVID-19 pneumonia based on chest CT and clinical findings. One patient was excluded from our analysis of correlation with  $\text{PaO}_2\text{:FiO}_2$  ratio and a further two patients were excluded from analysis regarding outcomes, due to insufficient LUS data (Figure 1).

Characteristics of the 28 patients are summarised in Table 1 and compared to patients included in the contemporaneous iteration of the United Kingdoms (UK) ICNARC report, published June 12<sup>th</sup>, 2020 [14]. 27/28 (96%) patients required invasive ventilation and the mean duration of admission was 18.5 days (range 2-52). 109 LUS assessments were performed, with a mean of four per patient (range: 1-10). 14 were performed in the prone position and 95 in the supine position. Classic features of COVID-19 pneumonia were seen in all patients, with diffuse B-lines and subpleural consolidation the most prominent features. The mean score (corrected) out of 36 for patients who were successfully weaned from invasive ventilation and survived to ICU discharge was 14.5,

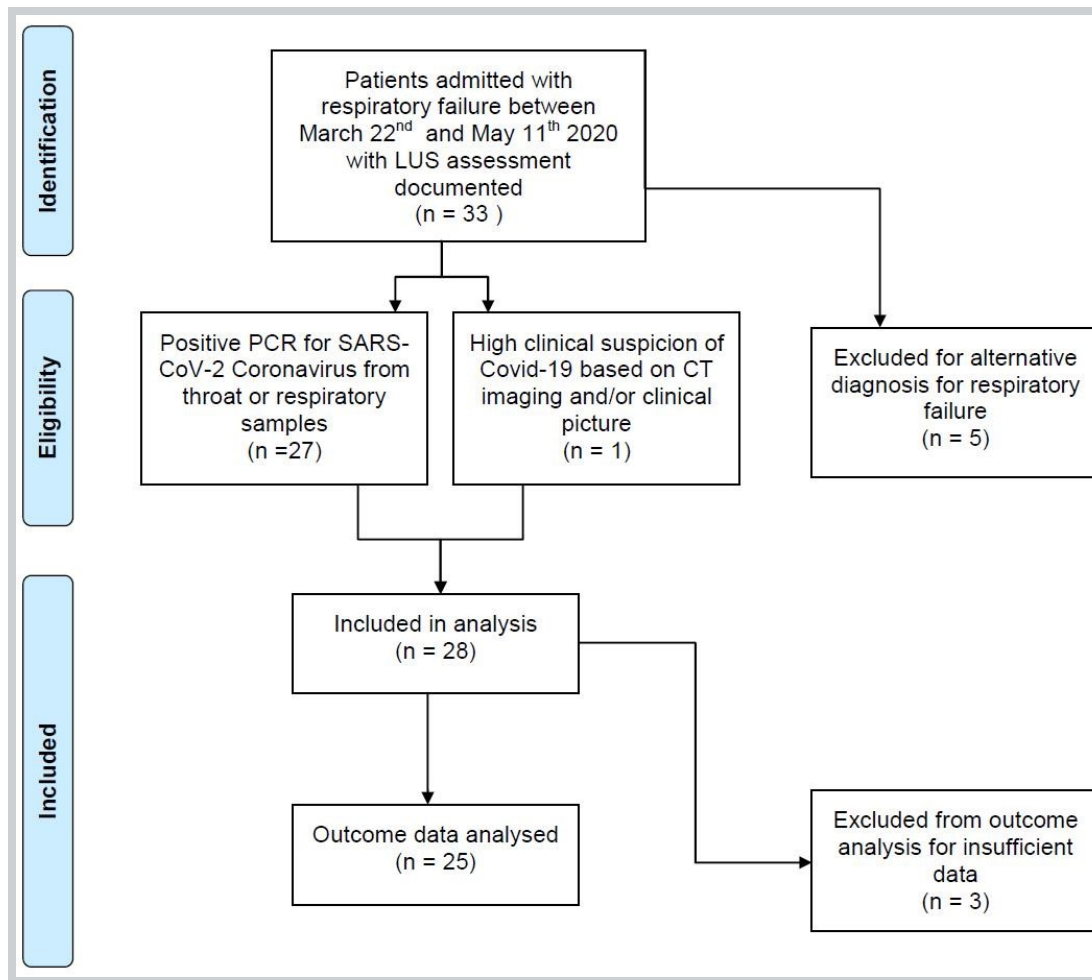


Figure 1. Flow diagram of patients included in analysis.

versus 20.6 for those who did not (difference of 6.1, 95% C.I. 9.8 to 2.5,  $p = 0.0021$ ).

Not all LUS assessments included all 12 regions. The majority of LUS assessments were performed with the patient in the supine position, all of which included eight anterior and lateral regions. To generate a standardised data set and allow meaningful correlation with clinical variables and outcomes, only findings from these eight antero-lateral assessments - giving a total worse possible score of aeration of 24 - were used for further analysis. This was not possible in 14 LUS assessments performed in the prone position. In total 95 LUS assessments from 27 patients (one patient was only assessed in the prone position and was therefore excluded) provided the scores of aeration and the number of disease-free regions for further analysis.

#### *Antero-lateral scores/SSS and $\text{PaO}_2\text{:FiO}_2$ ratio*

From the 27 patients included, correlation was demonstrated between antero-lateral scores of aeration and  $\text{PaO}_2\text{:FiO}_2$  ratio,  $r = -0.611$  (95% C.I. -0.72 to -0.47  $p < 0.0001$ ) Figure 2, and between the SSS number of disease-free regions and  $\text{PaO}_2\text{:FiO}_2$ ,  $r = 0.52$  (95% C.I. 0.35 to 0.65,  $p < 0.0001$ ) Figure 3.

#### *Antero-lateral scores/SSS and patient outcomes*

Table 2 summarises the relationship between lowest (best) antero-lateral scores of aeration and the highest (best) number of disease-free regions achieved by each patient and patient outcomes for the 25 patients included (outcomes are awaited in one patient and one patient was excluded as only one assessment – on admission following inter-hospital transfer – was performed). Receiver Operating Characteristics (ROC) analysis demonstrated that an antero-lateral score of  $\leq 9/24$  or an SSS of  $\geq 2$  disease-free regions at any point during critical care admission were most accurate at identifying patients who successfully weaned from mechanical ventilation and survived to ICU discharge. An antero-Lateral score of  $\leq 9/24$  had a sensitivity of 100% and a specificity of 83%, giving a PPV of 92% (95% C.I. 76% to 98%), a NPV of 100% and an accuracy of 94% (95% C.I. 77% to 99%). The Area Under the ROC Curve was 0.93. For the SSS,  $\geq 2$  disease-free regions had a sensitivity of 100% and a specificity of 92%, giving a PPV of 95% (95% C.I. 77% to 99%), a NPV of 100% and an accuracy of 97% (95% C.I. 81% to 99.9%). The Area Under the ROC Curve was 0.97.

14 patients were successfully weaned from mechanical

*Table 1. Baseline patient characteristics and medical history/indicators of acute severity in the 28 patients included, compared to data obtained from the United Kingdom Intensive Care National Audit and Research Centre (ICNARC), published on 12th June 2020. APACHE II = Acute Physiological Assessment and Chronic Health Evaluation II.*

Demographics	Study Cohort (N=28)	ICNARC Data (N=9777)
<b>Mean age (years) at admission (SD)</b>	61.7 (9.4)	58.7 (12.6)
<b>Sex, n (%)</b>		
Male	22 (78.6)	6908 (70.7)
Female	6 (21.4)	2864 (29.3)
<b>Race/Ethnicity, n (%)</b>		
White	13 (46.4)	6008 (67.1)
Mixed	3 (10.7)	154 (1.7)
Asian	2 (7)	1339 (15.0)
Black	4 (14.3)	869 (9.7)
Other	1 (3.6)	583 (6.5)
Not stated	5 (17.9)	n/a
<b>Body mass index, n (%)</b>		
<18.5	0	60 (0.7)
18.5-24.9	5 (17.6)	2292 (25.3)
25-29.9	10 (35.7)	3158 (34.8)
30-39.9	11 (39.3)	2856 (31.5)
40+	2 (7.1)	710 (7.8)
Medical History/indicators of acute severity	Study Cohort (N=28)	ICNARC Data (N=9777)
<b>Dependency prior to admission, n (%)</b>		
Able to live without assistance of daily activities	25 (89.3)	8589 (90.4)
Some assistance with daily activities	3 (10.7)	876 (9.2)
Total assistance with all daily activities	0	31 (0.3)
<b>Very serious co-morbidities, n (%)</b>		
Cardiovascular	0	59 (0.6)
Respiratory	0	106 (1.1)
Renal	0	160 (1.7)
Liver	0	40 (0.4)
Metastatic disease	0	46 (0.5)
Haematological malignancy	0	173 (1.8)
Immunocompromised	0	328 (3.4)
<b>Mean prior hospital length of stay in days (SD)</b>	1.0 (1.9)	2.5 (6.9)
<b>Mean APACHE II score (SD)</b>	14.6 (5.0)	14.9 (5.3)
<b>PaO<sub>2</sub>:FiO<sub>2</sub> ratio (based on lowest PaO<sub>2</sub> in first 24 hours), n (%)</b>		
≤13.3kPa (≤100mmHg)	10 (35.7)	3306 (37.2)
>13.3 and ≤26.7kPa (>100 and ≤200mmHg)	10 (35.7)	4267 (48.0)
>26.7kPa (>200mmHg)	8 (28.6)	1309 (14.7)



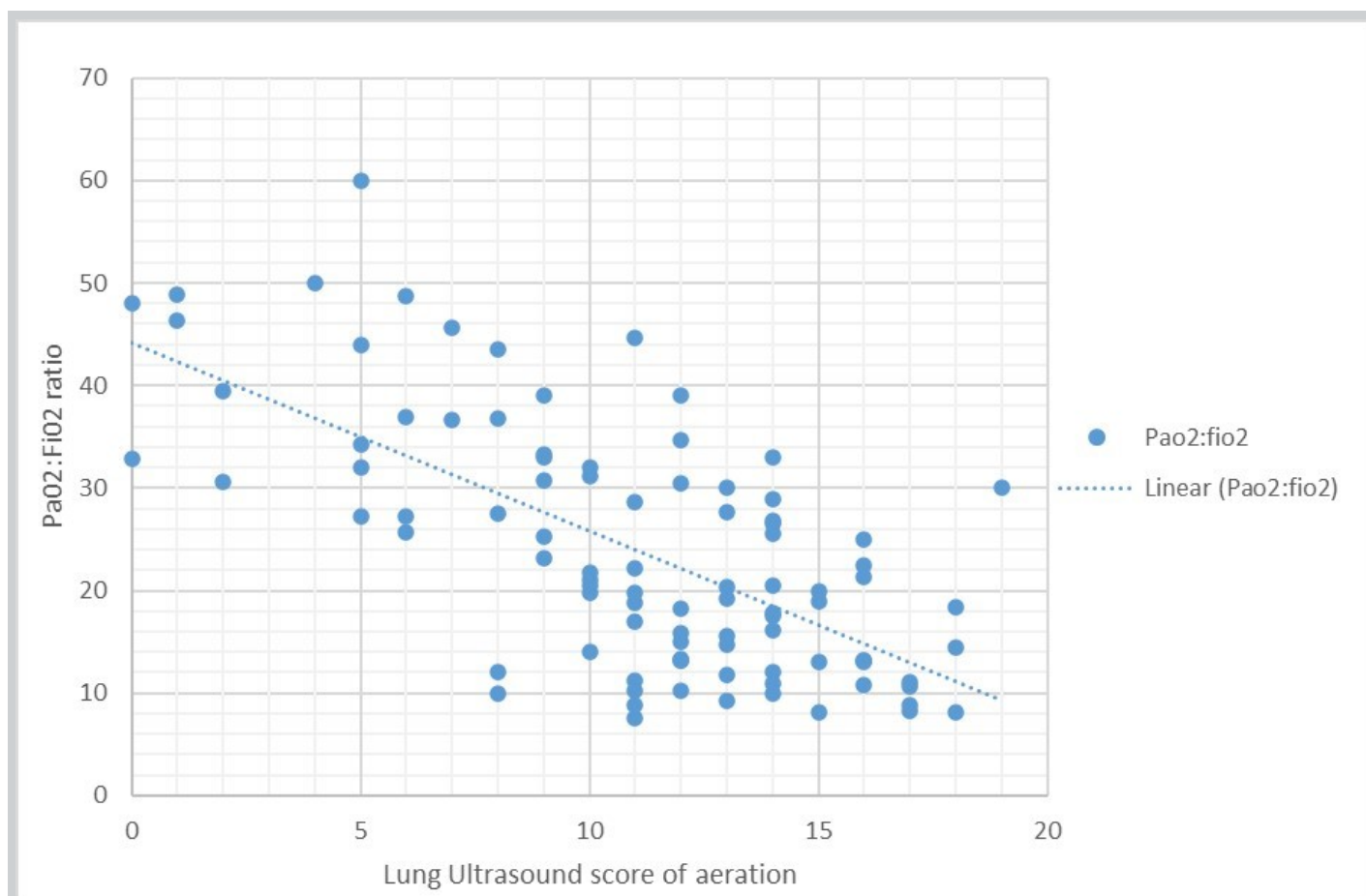


Figure 2. Graph demonstrating the correlation between lung ultrasound scores of aeration and PaO<sub>2</sub>:FiO<sub>2</sub> ratio

ventilation. 13/14 (93%) patients met both the above criteria, seven of which (54%) did so prior to transitioning to a spontaneous ventilation mode. Four of the remaining six patients met both criteria prior to extubation. One patient met both criteria and did not receive ventilatory support at any point and one patient met the criteria after extubation. One patient achieved an antero-lateral score of 9/24 prior to extubation but did not demonstrate any disease-free regions and subsequently required reintubation, not surviving to ICU discharge.

### Discussion

This study demonstrates that findings from serial LUS assessments can be used to monitor severity of respiratory failure in patients with COVID-19 pneumonia, demonstrating correlation with PaO<sub>2</sub>:FiO<sub>2</sub> ratio. The LUS score of aeration and SSS were also accurate at identifying patients with favourable outcomes.

The cohort of patients included is a predominantly representative sample. However, there is some divergence from the baseline characteristics of those included in the UK national database [14], particularly: patient ethnicity, mean prior hospital length of stay, and

the proportion of patients with moderate and mild respiratory failure. The study included 95 individual LUS assessments, with over a third of patients having five or more during their ICU admission, providing valuable longitudinal data. Xing et al have published on the progression of LUS findings in COVID-19 pneumonia over a four-week period, however they included only 36 assessments and did not correlate findings with other clinical variables or outcomes [8].

The LUS score of aeration, developed by Soummer et al, is validated in the context of Acute Respiratory Distress Syndrome (ARDS) [13]. Significant inter-individual variability, especially when differentiating separate from coalescent B-lines (a key component when generating the score of aeration) has been reported between experts in LUS [15,16]. This is likely to be exacerbated when performed by relative novices. The effect of interindividual variability in this cohort was minimised by ensuring all assessments included were performed or ratified by one clinician, however this approach is not pragmatic or scalable. COVID-19 pneumonia has been proposed to represent a distinct pathological process [17]. The SSS has advantages in the context of a global pandemic.

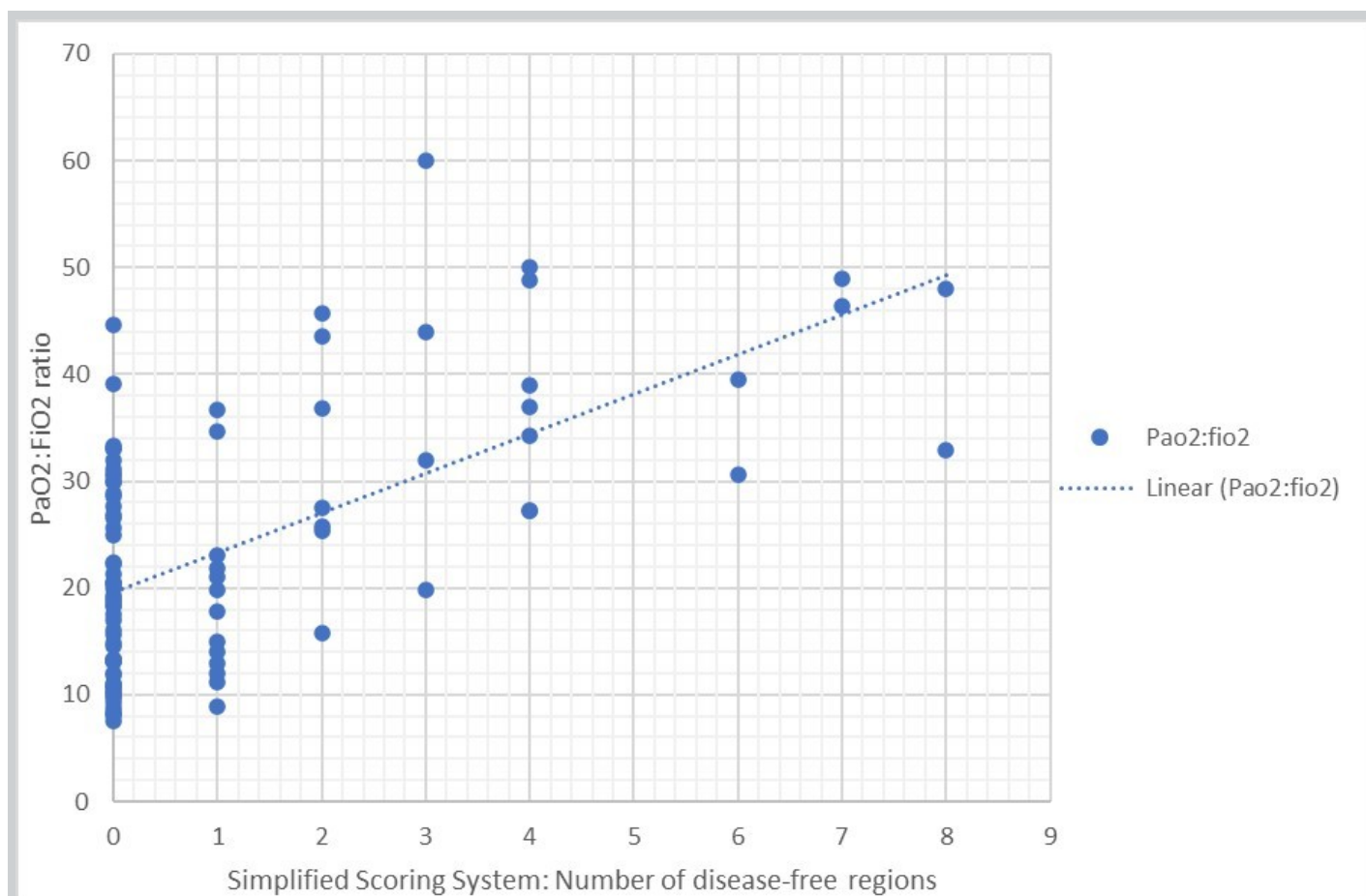


Figure 3. Graph demonstrating the correlation between the Simplified Scoring System (Number of disease-free regions) and PaO<sub>2</sub>:FiO<sub>2</sub> ratio

Owing to its binary nature it is likely to reduce interindividual variability and be easier to learn.

Correlation between the SSS and PaO<sub>2</sub>:FiO<sub>2</sub> was not as strong as that seen between the LUS score of aeration and PaO<sub>2</sub>:FiO<sub>2</sub>, however this requires confirmation. This may be because the simplified nature of the SSS does not record subtle fluctuations in loss of aeration which lead to worse PaO<sub>2</sub>:FiO<sub>2</sub> ratios. The ability of the SSS to predict favourable outcomes appears comparable to that of the LUS score of aeration. A possible explanation for this is that patients that do not survive develop long term lung injury because of COVID-19 infection and therefore do not demonstrate return of 'normal' LUS findings or achieve  $\geq 2$  disease-free regions. Those that survive, experience resolution of lung injury to the extent that whole regions appear disease free on LUS, which the SSS is equally adept at identifying.

Posterior regions were excluded from the final analysis to provide a standardised data set. This represents a pragmatic approach to the use of LUS in the supine position. Moving ventilated patients, especially at a time when staffing levels were stretched, to assess all 12

regions would have compromised their safety. Although a standardised data set from the supine position was used, assessment of posterior regions remains important, for example when assessing for the potential benefit of prone ventilation [18], especially as COVID-19 pneumonia may demonstrate posterior predominance [19].

As the LUS assessments were performed in a pragmatic fashion to aid in the management of critical ill patients, the timing of the LUS assessments was not standardised. Attempts were made to perform a LUS assessment at (or as close to) admission to critical care as possible, however this was not possible in all cases. A proportion (31%) of patients that achieved an antero-lateral score of aeration of  $\leq 9/24$  or an SSS of  $\geq 2$  disease free regions did so without ever achieving higher (worse) scores or fewer (worse) disease-free regions. In all these cases, the initial assessment was performed  $>7$  days after admission to critical care. This was due to a lack of competent clinicians being available on/around the time of admission in two cases and in two cases patients were transferred from other hospitals (for capacity reasons) after prolonged critical care admission. It is not possible

*Table 2. Relationship between best (lowest) antero-lateral scores of aeration, highest number of disease-free regions and patient's outcomes for the 25 patients included in the analysis.*

Patient No.	Lung ultrasound assessments		Outcomes	
	Best (lowest) Anterior-Lateral score of aeration	Highest number of disease-free regions	Successfully weaned from mechanical ventilation	Survived to ICU discharge
1	8	2	Yes	Yes
2	6	3	Yes	Yes
3	6	4	Yes	Yes
4	12	0	No	No
5	9	2	Yes	Yes
6	16	0	No	No
7	5	3	No	No
8	2	6	Yes	Yes
9	10	0	Yes	No
10	12	0	No	No
11	10	1	No	No
12	14	1	No	No
15	16	1	No	No
16	0	8	Yes	Yes
17	13	0	No	No
18	11	1	No	No
22	8	2	Yes	Yes
23	6	5	Yes	Yes
24	5	4	Yes	Yes
25	8	2	Yes	Yes
27	17	0	No	No
29	5	4	Yes	Yes
31	9	4	n/a	Yes
32	6	4	Yes	Yes
33	9	0	Yes	No

to ascertain if these patients had milder disease at admission to critical care or whether worse LUS scores were missed. However, whether due to more mild disease or resolution of severe disease, achieving an antero-lateral score of aeration of  $\leq 9/24$  or an SSS of  $\geq 2$  disease-free regions at any point during critical care admission was associated with a favourable outcome in our patient group.

This study has some significant limitations. This was a

small, retrospective analysis from a single site. The disease being investigated is new, with rapidly changing management. The timing of our assessments were not standardised and our analysis excluded the posterior regions of the lungs. As with any point of care ultrasound assessment, there is potential for inter-individual variability in the interpretation of LUS findings. As a result, the findings of our analysis should be considered hypothesis generating.

## Conclusions

Our retrospective analysis of 95 serial LUS assessments in a cohort of 28 patients with COVID-19 pneumonia demonstrates that findings correlate with PaO<sub>2</sub>:FiO<sub>2</sub> ratio as a marker of disease severity and could provide useful information regarding prognostication. We believe this simple, safe, and inexpensive bedside investigation can contribute to the wider patient assessment and aid decision making during the global COVID-19 pandemic. The easily learnt simplified scoring system warrants validating in a larger cohort.

## Declarations

*Ethics approval and consent to participate* - Ethics approval waived by the institution as this was a retrospective analysis of anonymised data.

*Consent for publication* – Not applicable.

*Competing interests and funding* – Non to declare

*Authors' contributions* – MG contributed to all stages, implementing a LUS service, performing and verifying LUS assessments, collecting and analysing the data and drafting and editing the manuscript. QO contributed by performing LUS assessments, collecting and analysing the data and editing the manuscript. SG contributed to data analysis and drafting and editing of the manuscript. AC contributed to implementation of the LUS service and editing the manuscript. All authors read and approved the final draft of the manuscript.

*Acknowledgements* – Thanks to Dr Tim Gould for assistance in editing the manuscript and adding clarity and Dr Lynne Armstrong for her advice and input.

## References

- Volpicelli G, Elbarbary M, Blaivas M, et al. International evidence-based recommendations for point-of-care lung ultrasound. *Intensive Care Med.* 2012;38:577–91.
- Lichtenstein DA, Mezière GA. Relevance of lung ultrasound in the diagnosis of acute respiratory failure: the BLUE protocol. *Chest.* 2008;134:117–25.
- Bouhemad B, Mongodi S, Via G, et al. Ultrasound for “Lung Monitoring” of Ventilated Patients. *Anesthesiology.* 2015;122:437–47.
- Wong A, Olusanya O, Wilkinson J, et al. Ultrasound in Times of COVID-19 [Internet]. *HealthManagement.* [cited 2020 Jun 29]. Available from: <https://healthmanagement.org/c/icu/issuearticle/ultrasound-in-times-of-covid-19>
- Shi H, Han X, Jiang N, et al. Radiological findings from 81 patients with COVID-19 pneumonia in Wuhan, China: a descriptive study. *The Lancet Infectious Diseases.* Elsevier; 2020;20:425–34.
- Peng Q-Y, Wang X-T, Zhang L-N, Chinese Critical Care Ultrasound Study Group (CCUSG). Findings of lung ultrasonography of novel corona virus pneumonia during the 2019–2020 epidemic. *Intensive Care Med.* 2020;46:849–50.
- Fiala MJ. Ultrasound in COVID-19: a timeline of ultrasound findings in relation to CT. *Clinical Radiology.* 2020;75:553–4.
- Xing C, Li Q, Du H, et al. Lung ultrasound findings in patients with COVID-19 pneumonia. *Crit Care* [Internet]. 2020 [cited 2020 May 13];24. Available from: <https://www.ncbi.nlm.nih.gov/pmc/articles/PMC7186946/>
- Volpicelli G, Lamorte A, Villén T. What's new in lung ultrasound during the COVID-19 pandemic. *Intensive Care Medicine* [Internet]. 2020 [cited 2020 May 14]; Available from: <http://link.springer.com/10.1007/s00134-020-06048-9>
- Smith MJ, Hayward SA, Innes SM, et al. Point-of-care lung ultrasound in patients with COVID-19 – a narrative review. *Anaesthesia.* 2020;75:1096–104.
- von Elm E, Altman DG, Egger M, et al. The Strengthening the Reporting of Observational Studies in Epidemiology (STROBE) Statement: Guidelines for Reporting Observational Studies. *PLoS Medicine.* 2007;4:e296.
- Bouhemad B, Zhang M, Lu Q, et al. Clinical review: Bedside lung ultrasound in critical care practice. *Crit Care.* 2007;11:205.
- Soummer A, Perbet S, Brisson H, et al. Ultrasound assessment of lung aeration loss during a successful weaning trial predicts post extubation distress\*. *Critical Care Medicine.* 2012;40:2064–72.
- ICNARC – Reports [Internet]. [cited 2020 Jun 16]. Available from: <https://www.icnarc.org/Our-Audit/Audits/Cmp/Reports>
- Haaksma ME, Smit JM, Heldeweg MLA, et al. Lung ultrasound and B-lines: B careful! *Intensive Care Medicine.* 2020;46:544–5.
- Corradi F, Via G, Forfori F, et al. Lung ultrasound and B-lines quantification inaccuracy: B sure to have the right solution. *Intensive Care Medicine.* 2020;46:1081–3.
15. BSTI COVID-19 Lung Ultrasound Guidance | The British Society of Thoracic Imaging [Internet]. [cited 2020 Jun 24]. Available from: <https://www.bsti.org.uk/standards-clinical-guidelines/clinical-guidelines/bsti-covid-19-lung-ultrasound-guidance/>
- Prat G, Guinard S, Bizien N, et al. Can lung ultrasonography predict prone positioning response in acute respiratory distress syndrome patients? *Journal of Critical Care.* 2016;32:36–41.
- Roshkovan L, Chatterjee N, Galperin-Aizenberg M, et al. The Role of Imaging in the Management of Suspected or Known COVID-19 Pneumonia. A Multidisciplinary Perspective. *AnnalsATS* [Internet]. 2020 [Cited 2021 October 18]; Available from: <https://doi.org/10.1513/AnnalsATS.202006-600FR>



# Development of a Cardiac Point-of-Care Ultrasound Curriculum for Anesthesia Residents in Brazil: It is Time to Act.

Fabio de Vasconcelos Papa, TSA/FASE, MSsCH<sup>1,2</sup>; Luiz Guilherme Villares da Costa, MD, PhD<sup>2</sup>

(1) Dalla Lana School of Public Health, University of Toronto  
(2) Albert Einstein Hospital, Sao Paulo, Brazil, Takaoka Anesthesia

## Abstract

Although the use of cardiac point-of-care ultrasound in anesthesia is well established, with strong evidence supporting its benefit while managing hemodynamically unstable patients during the perioperative period, there is a lack of standardized curriculums incorporating this diagnostic modality as part of the anesthesia residency training. This report aims to describe a FOCUS curriculum based on adult learning theories, and to suggest its implementation as part of the anesthesia residency training considering the learners' (i) previous experience with ultrasound, (ii) level of training in anesthesia, (iii) and other challenges that can impact the organization and delivery of this project.

## Description of curricular problem

The use of ultrasound in anesthetic practice is already well established such as in regional nerve blocks [1], central venous access [2], and perioperative transesophageal echocardiography [3].

Recently there has been a great increase in interest and the dissemination of the point-of-care ultrasound technique (POCUS) in the areas of intensive care, surgery, and emergency medicine, confirming that its use in perioperative medicine has a much broader potential, both to improve hemodynamic monitoring and for early diagnosis and management of complications [4].

Its use in the perioperative period is specifically well established in the following segments: (1) cardiac, (2) pulmonary, (3) hemodynamic assessment, (4) abdominal, (5) vascular access, (6) airway, and (7) assessment of intracranial pressure.

As a POCUS modality, focused cardiac US (FOCUS) is defined as the use of US at the bedside to evaluate the unstable patient and, within a specific list of diagnoses, individualizing the clinical treatment for a given situation based on the findings using binary and qualitative questions (yes/no). Its use by the anesthesiologist in the perioperative period is related to lower rates of complications and mortality in high-risk patients [5].

The advent of POCUS use in the anesthetic practice has introduced a new set of knowledge and skills, including knowledge of sonoanatomy and the skills of ultrasound scanning, image acquisition, interpretation, and transformation of a three-dimensional structure into a two-dimensional image.

In terms of training, there is no current consensus on what perioperative FOCUS comprises and no national curriculum in Brazil. The only published national ultrasound curriculum is from the Association of Anaesthetists of Great Britain and Ireland and the Intensive Care Society [6] being directed, without distinctions, to both anesthesia and intensive care trainees.

In order to acquire new skills to perform the FOCUS technique, there is a need to develop a training curriculum that considers the different training phases (handling of the device and acquisition of images, interpretation of images, and clinical correlation). In order to move from one phase to the next, the student needs to demonstrate proficiency in the previous phase. For this reason, there is still much debate around the creation of a training model for anesthesia residents so they can become more proficient and comfortable in performing the examination. It should also be considered the different phases of training, development, and experience within the anesthesia residency program and what is the best time (if any) in the residency program for the introduction of this curriculum.

The first specialty to introduce FOCUS in clinical practice was emergency, followed by intensive care medicine. In 2015, the International Federation of Emergency Medicine (IFEM) released a consensus document to guide the development of FOCUS training programs in Emergency Medicine [7]. According to this guide, despite having a more generic character, creating a training program should be based on the development of a basic program and a more advanced one regarding ultrasound

application. After that, the training is based on four distinct phases: introduction to the application, development of experience, achievement, and maintenance of competence.

Recommendations regarding intensive care training are based on the American College of Chest Physician Statement for Critical Care Ultrasonography. Like what has been described in emergency medicine, training is also composed of four different steps: introductory training, portfolio completion, competency assessment, and maintenance of competence [8].

Regarding training and education in FOCUS for anesthesiologists, despite many initiatives to create a formal curriculum, none has so far managed to be adopted as the gold standard. They are all very similar in the way they are built and in the steps that students must follow to advance in training [9].

In order to learn the FOCUS technique, there must be an integration of two essential factors: the learning of technical skills (acquisition, image optimization) and the interpretation and integration of the findings with the clinical picture. Given these two learning objectives, developing a curriculum based on Constructivist Social Theory associated with a teaching approach for the acquisition of procedural skills has the ideal components for learning the technique.

### Adult Learning Theory

There are many different adult learning theories, but they are all derived from the same concept that the way adults learn is different from how children learn.

The term Adult Learning Theory or Andragogy introduced by Malcolm Knowles [10] describes how the adult learning process differs from that of children, and it is based on five assumptions:

1. Adults are independent in their learning process.
2. They bring broad experience to the new learning process.
3. They value learning with practical results.
4. They are more interested in problem-centered approaches.
5. They bring an internal motivation to learn something new.

Constructivism is one of those learning theories based on the idea that learners actively construct or make their knowledge using their previous experience as a foundation and build on it with new things that they learn. There are many specific elements and principles of constructivism that shape the way the theory works and applies to students [11]:

6. Knowledge is personal.
7. Motivation is key to learning.
8. Learning is a social activity.
9. Learning is an active process.
10. Knowledge is constructed.
11. Learning is contextual.

In constructivism, the teacher act as a facilitator and not as a transmitter of knowledge. The primary idea of this theory is that learners construct their knowledge based on what they already know, posing emphasis on the active learning process.

The application of Constructivism to develop a new model of FOCUS training is based on some of the principles that make it the ideal theory for the development of a training model for anesthesia residents:

- Learner's "construct" their knowledge based on what they already know:

Anesthesia residents (especially during the final years of their training) can integrate different information regarding acute and unstable clinical problems faced during the perioperative period and have enough knowledge to adopt the concept of FOCUS into their clinical practice.

- The teacher is viewed not as a transmitter of knowledge but as a guide who facilitates learning.

Constructivism focuses on the collaborative nature of learning. Knowledge develops from how people interact with each other, their culture, and society at large. Students rely on others to help create their building blocks and learning from others helps them construct their knowledge and reality.

Vygotsky created two concepts that help to understand how constructivist social theory is used and what is the role of the teacher in this process: Zone of Proximal Development (ZPD) and Scaffolding [12].

- Zone of Proximal Development (ZPD): Vygotsky consistently defines the zone of proximal development as the difference between the current level of cognitive development and the potential level of cognitive development. He maintains that students can reach their learning goals by completing problem-solving tasks with their teacher or engaging with more competent peers. Vygotsky believed that a student would not reach the same level of learning by working alone. As a student leaves his zone of current development, he travels through the zone of proximal development towards his learning goal.
- Scaffolding: To help learners achieve independence, Vygotsky outlined scaffolding as a tool for growth.

Learners complete small, manageable steps to reach the goal. Working in collaboration with a skilled instructor or more knowledgeable peers helps students make connections between concepts. As learners grow within their zone of proximal development and become more confident, they practice new tasks with the social support that surrounds them. Vygotsky maintains that learning occurs through purposeful, meaningful interactions with others.

Acquisition of procedure skills is an essential element in health professions education [13]. Traditionally, procedures were taught using a "see one - do one" approach, meaning that a teacher demonstrates and describes a procedure, and afterward, the students are asked to practice the same procedure. Although this approach has been prevalent and is still used in some situations, it is an unsystematic and unstructured approach not following the current principles of adult learning and sometimes putting the patient at risk. A more recent approach described by Walker and Peyton describes a stepwise teaching approach consisting of four different steps [14]: demonstration, deconstruction, comprehension, and performance. As demonstrated in a systematic review and meta-analysis by Giacomino et al. [15], it proved to be more effective in teaching and acquiring new procedural skills.

### **Curricular solution**

The creation of a training model based on the Constructivism Theory considers the basic knowledge of the anesthesiologist in training regarding the use of ultrasound for central venous access and regional nerve blocks and extrapolates it for use with the goal of point-of-care for diagnosis and management of common causes of hemodynamic changes in the perioperative period. It also should take into consideration the importance of the concept of ZPD and scaffolding with the instructor having the role of creating different stages of learning and training in order to gradually deepen the technical and theoretical knowledge of the student, avoiding the cognitive load but at the same time to help them to acquire independence in the realization of the technique and interpretation of the results.

In terms of technical skills acquisition, the student must observe the performance of the correct examination technique performed by the proficient anesthesiologist in an environment free from the pressure generated by an unstable patient, where the result of this assessment will change the clinical approach. An initial phase of varying duration where training is carried out in a simulation environment can offer the ideal opportunity to develop technical and cognitive skills related to the technique. In addition, it is essential to consider in the development of

the training program the concept of cognitive load to break the process into small parts (weekly) for a better learning experience.

Based on all the concepts exposed in the sessions above, the curriculum for training anesthesia residents in the FOCUS modality should be based on a horizontal program to be applied to all anesthesia residents, respecting the different training stages and composed of:

**Phase 1:** Program of formal classes with topics related to image acquisition and optimization, handling the device, choice of the probe, and most common clinical scenarios found in the operating room (myocardial infarct, tamponade, pulmonary embolism, hypovolemia). After the student participates in the entire class program and is theoretically assessed (MCQ) with a satisfactory result, he/she would be able to progress to the second training stage.

**Phase 2:** Acquisition and interpretation of images performed on the simulator to familiarize the student with the handling of the device and what to expect from the technique. After training in the simulator and proficiency assessment, they could progress to phase 3.

**Phase 3:** Final part of the training consisting of examinations performed on actual, low risk and stable patients undergoing elective surgical procedures under the direct supervision of the instructor. If proficiency in the technique is demonstrated and after a logbook of 30 exams (as suggested in the literature [16]), there will be a progression towards the realization of the exam in unstable patients with the correlation of the exam findings and decision making.

Consideration needs to be made about placing residents of different years at the same level of training. Although there is a significant difference of experience between the resident in the first and last year, teaching this diagnostic modality is valid from the beginning of the residency and improves patient care. Over time and with new classes of residents starting, the more experienced ones (having had training from the beginning) will be able to facilitate members to learn more junior residents.

Some challenges can threaten the successful implementation of the proposed curriculum:

1. The limited number of anesthesiologists proficient in the FOCUS technique willing to participate in the training program.
2. Lack of formal knowledge in simulation, learning theories, and feedback by the anesthesiologists involved.
3. Need for protected time (outside the operating room) for teaching the technique by both anesthesiologists and residents.

4. Absence of a worldwide formal training program in the FOCUS technique for the anesthesia specialty.
5. Although the literature suggests between twenty-five and thirty exams performed under direct supervision, there is no consensus regarding the minimum number of exams after which the student can be considered proficient and able to perform the exam and make clinical decisions based on the findings [16].

## Conclusion

The development of a training program aimed at the anesthesia resident must consider the particularities of the specialty (routine within the operating room) and the type of situations that can be encountered in daily clinical practice (e.g., hemodynamic instability that requires diagnosis and immediate treatment). Despite the importance of the topic, there is no current consensus on what FOCUS training comprises and no national curriculum in Brazil (or elsewhere).

The adoption of the constructivist model for the development of a training program is based on the fact that the anesthesia resident already has some knowledge regarding the use of ultrasonography (either for performing peripheral blocks or obtaining venous access) and can use it as a starting point to learn this new technique. In addition, the instructor can act as a facilitator of this learning using the concepts of ZPD (Zone of Proximal Development) and Scaffolding described by Vygotsky, creating different stages that must be finalized in order to progress to a more advanced stage, culminating in independence for the performance, interpretation, and integration of the examination findings.

The goal of this paper was to describe a training model based on the Constructivist Learning Theory (based on the anesthesia residents' previous knowledge of ultrasound) to facilitate, optimize and organize the learning of the focused cardiac ultrasound point-of-care technique based in a program composed of theoretical and practical components in order to familiarize the student with the concept and importance of the technique, progressing towards the development of new skills for the exam, culminating in the interpretation of the results and integration with the clinical picture found aiming at the decision making with the objective of better care to the hemodynamically unstable patient.

## Disclosures

None

## References

1. Gray AT. Ultrasound-guided regional anesthesia: current state of the art. *Anesthesiology*. 2006; 104:368---73.
2. Wu SY, Ling Q, Cao LH, et al. Real-time two-dimensional ultra-sound guidance for central venous cannulation: a meta-analysis. *Anesthesiology*. 2013; 118:361---75.
3. Shore-Lesserson L, Moskowitz D, Hametz C, et al. Use of intraoperative transesophageal echocardiography to predict atrial fibrillation after coronary artery. *Anesthesiology*. 2001;95:652---8.
4. Chen R. Synopsis of the point-of-care ultrasound assessment for perioperative emergencies. *Can J Anesth/J Can Anesth* (2019) 66:448--46. <https://doi.org/10.1007/s12630-019-01303-0>.
5. Canty DJ, Royse CF, Kilpatrick D, et al. The impact on cardiac diagnosis and mortality of focused transthoracic echocardiography in hip fracture surgery patients with increased risk of cardiac disease: a retrospective cohort study. *Anaesthesia*. 2012;67:1202---9.
6. Association of Anaesthetists of Great Britain & Ireland. Ultrasound in Anaesthesia and Intensive Care: A Guide to Training, 2011. Available from URL: <http://www.aagbi.org/publications/publications-guidelines/ultrasound-anaesthesia-and-intensive-care-guide-training>.
7. Atkinson P, Bowra J, Lambert M, Lamprecht H, Noble V, Jarman B. International Federation for Emergency Medicine point of care ultrasound curriculum. *CJEM*. 2015 Mar;17(2):161-70. doi: 10.1017/cem.2015.8. PMID: 26052968.
8. Expert Round Table on Ultrasound in ICU. International expert statement on training standards for critical care ultrasonography. *Intensive Care Med*. 2011 Jul;37(7):1077-83. doi: 10.1007/s00134-011-2246-9. Epub 2011 May 26. PMID: 21614639.
9. Ramsingh D, Rinehart J, Kain Z, Strom S, Canales C, Alexander B, Capatina A, Ma M, Le KV, Cannesson M. Impact assessment of perioperative point-of-care ultrasound training on anesthesiology residents. *Anesthesiology*. 2015 Sep;123(3):670-82. doi: 10.1097/ALN.0000000000000776. PMID: 26181338.
10. Knowles MS and Associates. *Andragogy in action: applying modern principles of adult learning*. San Francisco: Jossey-Bass, 1984.
11. Western Governors University; What is Constructivism? <https://www.wgu.edu/blog/what-constructivism2005.html#:~:text=Constructivism%20is%20an%20important%20learning,your%20experiences%20as%20a%20learner>.
12. Piaget's theory of cognitive and affective development: Foundations of constructivism, 5<sup>th</sup> ed.
13. Grantcharov,T.; Reznick, R.; Teaching Procedural Skills. *BMJ* 2008; 336:1129-31  
doi:10.1136/bmj.39517.686956.47.
14. Walker M, Peyton J. 1998. Teaching in theatre. Teaching and learning in medical practice.  
Rickmansworth: Manticore Europe Limited, 171180.
15. Giacomino K, Caliesch R, Sattelmayer KM. 2020. The effectiveness of the Peyton's 4-step teaching approach on skill acquisition of procedures in health professions education: A systematic review and meta-analysis with integrated meta-regression. *PeerJ*8:e10129 <http://doi.org/10.7717/peerj.10129>.
16. Spencer KT, Kimura BJ, Korcarz CE, Pelikka PA, Rahko PS, Siegel RJ. Focused cardiac ultrasound: recommendations from the American Society of Echocardiography. *J Am Soc Echocardiogr*. 2013 Jun;26(6):567-81. doi: 10.1016/j.echo.2013.04.001. PMID: 23711341.



## Editorial Board

### Editor In Chief

Benjamin Galen, MD

### Former Editor In Chief and Founder

Amer Johri, MD

### Anesthesiology

Wilfredo Puentes, MD

Rob Tanzola, MD

### Cardiology

Ritu Thamman, MD

### Emergency Medicine

Wilma Chan, MD

Casey Glass, MD

### Global Health

Gordon Johnson, MD

### Internal Medicine

Trevor Jensen, MD

Tanping Wong, MD

### Nephrology

Abhilash Koratala, MD

Nathaniel Reisinger, MD

### Pediatrics

Ria Dancel, MD

Beryl Greywoode, MD

### Pulmonary and Critical Care

Cameron Baston, MD

Segun Olusanya, MD

**Managing Editor:** Julia Herr, MSc

**Social Media Editor:** Braeden Hill

## Call for Submissions

Physicians, Researchers, and Educators are invited to contribute articles to upcoming issues of POCUS Journal.

For detailed information, visit [pocusjournal.com/about/instructions-to-authors](http://pocusjournal.com/about/instructions-to-authors).

For inquiries or proposed topics, please contact the editors at [submit@pocusjournal.com](mailto:submit@pocusjournal.com).

## About Us

**POCUS Journal** is dedicated to the advancement of research and the promotion of education in the field of point-of-care ultrasound.

POCUS journal can be found online at [pocusjournal.com](http://pocusjournal.com).

You can receive email updates when a new issue is available by subscribing to the POCUS Journal email newsletter. Visit [pocusjournal.com/subscribe](http://pocusjournal.com/subscribe).

To submit your case study or letter for publication in POCUS Journal, visit [pocusjournal.com/submit](http://pocusjournal.com/submit).

**If you would like to advertise in POCUS Journal, make a donation or announcement, email at [info@pocusjournal.com](mailto:info@pocusjournal.com)**

The online version of Vol. 06 Iss. 02 of POCUS Journal is available at [ojs.library.queensu.ca/index.php/pocus/index](http://ojs.library.queensu.ca/index.php/pocus/index) and includes additional media and images from the case studies.

## POCUS Journal is a publication by CINQ

POCUS Journal is supported by the Cardiovascular Imaging Network at Queen's (CINQ), and the Queen's University Library.

Visit CINQ at [cinqlab.com](http://cinqlab.com) to learn more.

CINQ  
76 Stuart St.,  
Kingston, ON Canada, K7L 2V7